# ISMISS TURKEY


## 3rd ISMISS Congress in Turkey on Minimal Invasive Spine Surgery and Interventional Treatments


www.ismissturkey.org

**April 2 - 4**
**2010**
**Istanbul TURKEY**
Polat Renaissance Hotel

# Abstract Book

# ISMISS TURKEY

INTERNATIONAL SOCIETY FOR MINIMAL INTERVENTION IN SPINAL SURGERY

Affiliated With SICOT

## 3rd ISMISS Congress in Turkey on Minimal Invasive Spine Surgery and Interventional Treatments

# Abstract Book

# ISMISS - President s greeting address to the 3rd ISMISS Congress in Turkey on Minimal Invasive Spine Surgery and Interventional Treatments

*Leu Hj., PD Dr.med., President ISMISS 2008-2011*

*Bethania Spine Base, Orthopaedic Spinal Surgery, Klinikum Bethanien*

*CH-8044 Z rich / Switzerland b ethania-spine@bluewin.ch*

Evolution is our life. From first lumbar disc decompression concept by Mixter & Barr (US) in 1934 evolution to minimal invasive spinal surgery took around 50 years, what corresponds to two professional active life cycles of a professional spinal surgeon. Since introduction of endoscopic surgery another 25 years are over. Many new procedures araised and disappeared. A need for exchange in experience and mutual instructions soon became evident. Since its foundation in 1989 by the three founding members S.Hijikata (Jp), P.Kambin (US) and A.Schreiber (CVH), the International Society for Minimal Invasive Spinal Surgery (ISMISS / www.ismiss.com affiliated to SICOT) seeks to foster minimal invasive technologies and aims for exchange of well controlled information and methodical instruction in the rapidly evolving field of this young branch of spinal surgery. So, beside its upraise in Europe and US, since the nineties a rapid growth was to observe in Korea and Japan; in the last years also in China and ASEAN countries. Interested groups and active spinal surgeons pioneered several new techniques and report their experiences in periodically organized meetings under the auspices of ISMISS. The goal remains to allow first hand information on new techniques, their concepts with well defined indications, limits and results. So all over the world several established courses are now periodically organized under the auspices of ISMISS under this commitment, such as this Turkish Courses under direction of Dr.Satana, now already in its third edition.

Beside technical and operative aspects also clinical analysis of indications, relevant learning-curves and follow-up criteria deserve our interest in worldwide economically restricted conditions and an evident need for outcome quality control. So also a need for common rules for good practice became evident within the ISMISS to define and publish (see under www.issmiss.com) common sense definitions and guidelines, helping so all active partners in the field of minimal invasive spinal surgery to orient themselves in the rapid evolution of this field.

Now in the over two decades of ISMISS activities, it is our honor and pleasure to auspice again this already third specific meeting in Turkey. We are convinced that it will, as its previous editions, mirror an up-date on established techniques in this field, the 2010's state of the art and flash on upcoming innovative developments in spinal surgery. We congratulate and thank Dr.Satana Tolgay, ISMISS national representative of Turkey, and his group for the once more amazing organization of this third meeting. It is most encouraging to see the large interest of our colleges in Turkey. We remain convinced that only bundling of common interest and forces can help to foster our goals. With such a common sense and open exchange local and international pioneers and experts sharing the course faculty promise to contribute to a ISMISS-typically vivid and collegial atmosphere again in the third Turkish meeting and making many contacts to build strong bridges worldwide within the colleges active in this fascinating filed of spinal surgery.

March 2010
Hansjoerg F. Leu, M.D.
President ISMISS 2008-2011

*"If you do not know where you are headed, your destination does not matter."*
*Peter Drucker*

That nuclear energy could well be used to destroy humanity shows the graveness of the question: "Does science have ethical responsibilities?" So, like other treatments, surgery should benefit all of humanity.

This belief has led to a key development for all surgical treatments whose mottos no more serve the main philosophy behind minimally invasive surgery. Those involved in surgical treatment should be concerned with ensuring minimal invasiveness with less trauma rather than simply smaller incisions. The use of endoscopic surgery is inevitable to that end. The mission of the International Society for Minimal Intervention in Spinal Surgery (ISMISS), the scientific knowledge sharing platform enabling surgeons to meet and follow the latest trends in surgery, continues with this congress.

In saying "If you do not know where you are headed, your destination does not matter", Peter Drucker pointedly emphasizes that a prudent approach is required to the introduction of surgical innovations, and also to keep surgery in line with contemporary technologies.

While it seems to be in conflict with classic surgery, endoscopic spinal surgery is sure to open new horizons.

We call on all our colleagues to welcome this development and get involved in knowledge sharing on our platform.

**Tolgay Satana, MD**
**Course Co-ordinator**

# ORGANIZING COMMITTEE

**Honorary President**
John Chiu (USA)

**President**
Hansjoerg Leu (Switzerland)

**Co-President**
Mehmet Zileli (Turkey)

**Course Coordinator**
Tolgay Satana (Turkey)

**Scientific Secretariat**
Altay Sencer (Turkey)
Cumhur Kilincer (Turkey)

**Award Committee**
Altay Sencer
Cumhur Kilincer
Figen Yağmur Aslan
Hansjoerg Leu
Mehmet Ali Tumoz
Mehmet Zileli
Tolgay Satana

**Organizing Committee**
Ali Güven Fincan
Ali Güven Yorukoglu
Altay Sencer
Burcu Candan
Cumhur Kilincer
Figen Yagmur Aslan
Kamil Barlas
Kayahan Sahinoglu
Mehmet Altug
Mesut Batmaz
Murat Erguven
Mustafa Anter
Taylan Temel
Ufuk Soylu

# FACULTY

Akira Dezawa
Alexander Levshyn
Alexander Sirenko
Ali Guven Yorukoglu
Ali Güven Fincan
Altay Sencer
Andrea Almeida
Andrey Kobizev
Andrey Popov
Anthony Yeung
Artem Skidanov
Arvind Bhave
Athanasios Giannakopoulos
Ayhan Comert
Bambang Darwono
Burak Ozgur
Burcu Candan
Charis Matzaroglou
Christof Birkenmaier
Cumhur Kilincer
Daniel Gastambide
Elvan Erhan
Farnad Imani
Figen Yagmur Aslan
Fujio Ito
Fusun Uysal
George Roumeliotis
Halil Algan
Halil Ibrahim Acar
Hansjoerg Leu
Hikmet Ulug
Howard S An
Hussien El-Maghraby
Jae-Yoon Chung
Jin Sung Kim
John Chiu
Kamil Barlas
Kayahan Sahinogl
Koichi Sairyo
Konstantin Gordienko
Konstantyn Popsuishapka
Kresimir Rotim
Lester Wilson
Maghnia El-Kasmi
Markos Ioannou
Mehmet Ali Tumoz
Mehmet Altug
Mehmet Zileli
Mesut Batmaz
Michael Schubert
Mohamed Mohi Eldin
Murat Erguven
Mustafa Anter
Nils Haberland
Nurettin Luleci
Ozkan Akinci
Patrick Hahn
Pil-Sun Choi
Robert Hensinger
Robert Saftic
Sadaaki Nakai
Sebastian Ruetten
Semih Ozdemir
Serdar Kabatas
Serra Sencer
Shing-Sheng Wu
Stefan Hellinger
Taylan Temel
Tolgay Satana
Ufuk Soylu
Vasil Shimon
Vijay Goni
Vladimir Radchenko
Wolfgang Rauschning
Zheng Zhaomin

# *Scientific Program*

## April 2, 2010

| | | |
|---|---|---|
| **08:30-11:00** | **Live Surgery on Ò ndoscopic, Lumbar and Cervical DiscectomyÓ** | **John Chiu, Stefan Hellinger, Burak Ozgur, Tolgay Satana** |
| | Microscopic Discectomy Through the Tubular Retractor | Burak Ozgur |
| | Lumbar Discectomy | Stefan Hellinger |
| | Cervical Discectomy | John Chiu |
| **14:00-17:00** | **Pre-Congress Cadaver Hands-On Workshop on Ò oraminal and Endoscopic Spinal AnatomyÓ** | **John Chiu, Stefan Hellinger, Burak Ozgur, Tolgay Satana** |
| | Basic Principles of MISS techniques | Tolgay Satana |
| | Hands on workshop with cadavra: Percutan endoscopic lumbar discectomy - Percutan endoscopic cervical discectomy - Endoscopic thorasic discectomy | John Chiu, Stefan Hellinger, Burak Ozgur, Tolgay Satana |

## April 3, 2010

| | | | |
|---|---|---|---|
| 08:30-08:35 | Welcome address | Mehmet Zileli | |
| 08:35-08:45 | Presidential greeting address of ISMISS | Hansjoerg Leu | |
| | **Panel 1 - Basic Principles** | **Hansjoerg Leu, Mehmet Zileli** | |
| 08:45-08:55 | History of Minimal Invasive Spinal Surgery | Mehmet Ali Tumoz | L-1 |
| 08:55-09:05 | Anatomy of the lumbar intervertebral foramen | Halil Ibrahim Acar | L-2 |
| 09:05-09:15 | Vascular anatomy and its relationship to the lumbar intervertervertebral discs | Ayhan Comert | L-3 |
| 09:15-09:25 | Fundamental anatomic aspect to safely perform pedicle based lumbar spine stabilization | Pil-Sun Choi | L-4 |
| 09:25-09:35 | Spinal Radiology Imaging of low back pain | Serra Sencer | L-5 |
| 09:35-09:45 | Awaken and general Anesthesia in MISS | Ozkan Akinci | L-6 |
| 09:45-09:55 | Outcome measures in Low Back Pain | Fusun Uysal | L-7 |
| 09:55-10:05 | Interventional techniques for low- back pain | Elvan Erhan | L-8 |
| 10:05-10:10 | Discussion | | |
| 10:10-10:30 | ***Coffee Break*** | | |

| | | | |
|---|---|---|---|
| | **Master Lecture** | **Christof Birkenmaier, Burak Ozgur** | |
| 10:30-10:45 | ISMISS and endoscopic spinal surgery: Facts and update 1989-2010 | Hansjoerg Leu | ML-1 |
| 10:45-11:00 | Anatomical rationales for Minimally Invasive Spine Surgery | Wolfgang Rauschning | ML-2 |
| 11:00-11:05 | Discussion | | |
| | **Master Lecture** | **Stefan Hellinger, Wolfgang Rauschning** | |
| 11:05-11:20 | Minimally invasive surgery on the pediatric spine | Robert Hensinger | ML-3 |
| 11:20-11:35 | Novel treatments of degenerative lumbar disc disease | Howard S An | ML-4 |
| 11:35-11:40 | Discussion | | |
| | **Master Lectures** | **Daniel Gastambide, Sebastian Ruetten** | |
| 11:40-11:55 | Endoscopic spine surgery | Fujio Ito | ML-5 |
| 11:55-12:10 | Is there a place for minimal invasive and endoscopic surgery on the lumbar and cervical spine? | Stefan Hellinger | ML-6 |
| 12:10-12:25 | Percutaneous Endoscopic Lumbar Discectomy by contralateral approach for distally migrated hernia | Jae-Yoon Chung | ML-7 |
| 12:25-12:30 | Discussion | | |
| 12:30-13:15 | ***Lunch*** | | |
| **12:30-13:15** | **Luncheon Meeting of ISMISS Board** | | |

| | | | |
|---|---|---|---|
| | **Program Lectures** | **Semih Ozdemir, Hikmet Ulug** | |
| 13:15-13:25 | Radiation Safety in MIS spine surgery: Does wearing protective gloves help? | Anthony Yeung | L-9 |
| 13:25-13:35 | Learning curve in the interlaminar and transforaminal full endoscopic lumbar discectomy: Pitfalls and crucial points | Hikmet Ulug | L-10 |
| 13:35-13:45 | Endoscopic Transforaminal Microdecompressive Lumbar Disc Surgery with GPS for Morbid Obese Patient | John Chiu | L-11 |
| 13:45-13:55 | Full endoscopic operation with interlaminar and trans-/extraforaminal approach of lumbar juxtafacet cyst - Prospective randomized controlled study with 60 patients | Patrick Hahn | L-12 |
| 13:55-14:05 | Full-endoscopic posterior foraminotomy for operation of cervical disc herniations – Prospective comparison to ACDF | Semih Ozdemir | L-13 |
| 14:05-14:10 | Discussion | | |
| | **Master Lecture** | **Jae-Yoon Chung, Zheng Zhaomin** | |
| 14:10-14:25 | Full-endoscopic operations of the cervical spine in disc herniations | Sebastian Ruetten | ML-8 |
| 14:25-14:40 | Anterior Endoscopic Microdecompressive Cervical Discectomy (AECD) with GPS | John Chiu | ML-9 |
| 14:40-14:45 | Discussion | | |

| | | | |
|---|---|---|---|
| | **Panel 2: Endoscopic Spine Techniques** | **Fujio Ito, Tolgay Satana** | |
| 14:45-14:55 | Dorsal Endoscopic Rhizotomy of the dorsal ramus targeting the medial, intermediate and lateral branch for chronic nondiscogenic axial back pain | Anthony Yeung | L-14 |
| 14:55-15:05 | Cure of lombosciatalgias, issues and prospects, Intervertebral surgery and new trends, about the surgical techniques | Daniel Gastambide | L-15 |
| 15:05-15:15 | The full-endoscopic interlaminar versus microsurgical laminotomy technique for bilateral spinal decompression of lumbar central stenosis: A prospective, randomized, controlled study | Patrick Hahn | L-16 |
| 15:15-15:25 | Intra-/extraforaminal lumbar disc herniation - Prospective randomized comparison of full-endoscopic technique with trans-/extraforaminal access versus microsurgical technique | Semih Ozdemir | L-17 |
| 15:25-15:35 | Evolving Minimally Invasive Endoscopic Spine Surgery: A surgeonce perspective and emerging Technical Considerations | John Chiu | L-18 |
| 15:35-15:45 | Endoscopic Transforaminal Discectomy (ETD) | Michael Schubert | L-19 |
| 15:45-15:50 | Discussion | | |
| 15:50-16:15 | ***Coffee Break*** | | |
| **16:15-16:35** | **Debate Session - Round Table :** | **Anthony Yeung, Mehmet Zileli** | |
| | Microscopic discectomy versus Percutaneous discectomy<br>Anthony Yeung, Burak Ozgur, Hansjoerg Leu, Howard S An, Jae-Yoon Chung, John Chiu, Mehmet Zileli, Sadaaki Nakai, Sebastian Ruetten, Stefan Hellinger, Fujio Ito, Zheng Zhaomin | | |
| 16:35-16:40 | Discussion | | |
| | **Program Lectures** | **Patrick Hahn, Vladimir Radchenko** | |
| 16:40 -16:50 | Full-endoscopic operation of lumbar recess stenosis compared to the microsurgical technique | Maghnia El-Kasmi | L-20 |
| 16:50-17:00 | Full-endoscopic operation of lumbar disc herniation versus the microsurgical technique - 24 months results of a prospective randomized comparative study | Andrea Almeida | L-21 |
| 17:00-17:10 | Diagnostic and Treatment of after Lumbar Facet Joints Denervation | Alexander Sirenko | L-22 |
| 17:10-17:20 | Study of Percutaneous Vertrbroplasty in Osteoporosis Vertebral Compression Fractures using Various ractures compositive materials | Andrey Popov | L-23 |
| 17:20-17:30 | Interlaminar and lateral transforaminal full-endoscopic operation of recurrent lumbar disc herniations in patients with conventional previous operations | Athanasios Giannakopoulos | L-24 |
| 17:30-17:40 | The Lumbar Interspinous Distraction, Stabilization (IDS) Decompression devices, (Initial Experience of a Comparative Study) | Mohamed Mohi Eldin | L-25 |

| | | | |
|---|---|---|---|
| 17:40-17:50 | Endoscopic Transforaminal Discectomy for recurrent Lumbar Disc Herniation | Michael Schubert | L-26 |
| 17:50-18:00 | Treatment of protrusion and non-sequestered hernias of intervertebral discs using diode laser | Vasil Shimon | L-27 |
| 18:00-18:10 | Minimal Invasive Surgery for spinal trauma: Outcome of percutaneous vertebral augmentation with percutaneous pedicle screw fixation | Hussien El-Maghraby | L-28 |
| 18:10-18:20 | Monitoring anaesthesia control during kyphoplasties | Charis Matzaroglou | L-29 |
| 18:20-18:30 | Quality of life anxiety and depression improved after Kyphoplasties for metastatic disease | Charis Matzaroglou | L-30 |
| 18:30-18:35 | Discussion | | |

**17:30-18:30 Poster Presentations**

| | | |
|---|---|---|
| - Retained, asymptomatic bullet in D11-D12 intervertebral disc space: A Case Report | Vijay Goni | P-1 |
| - The results of Percutaneous Disc Decompression Utilizing - Dekompressor in patiants with Chronic Lumbar Discogenic pain | Farnad Imani | P-2 |
| Efficacy and safety of Balloon Kyphoplasty - Are high cement volumes required? | Markos Ioannou | P-3 |
| - Six months results of cervical radiofrequency ablation neurotomy in patients with chronic neck pain | Markos Ioannou | P-4 |
| - Complications after surgical management of Isiopathic Scoliosis in Children | Andrey Kobizev | P-5 |
| - Percutaneous endoscopic transforaminal lumbar epidural abscess debridement and drainage after subarachnoid hemorrhage; a case report | Ali Guven Yorukoglu | P-6 |

19:30-20:30 ***Welcome Party***

# April 4, 2010

| | | | |
|---|---|---|---|
| | **Program Lectures** | **Halil Algan, Mustafa Anter** | |
| 08:00 - 08:10 | Unilateral Minimal Access TLIF surgery | Lester Wilson | L-31 |
| 08:10 - 08:20 | Transforaminal endoscopic discectomy and thermal annuloplasty for the treatment of discogenic back pain | Kresimir Rotim | L-32 |
| 08:20 - 08:30 | Minimally invasive CT guided trans-foraminal perineural root injection in treatment of radiculopathy | Hussien El-Maghraby | L-33 |
| 08:30-08:40 | Long term results of vertebral augmentation in 260 consecutive pathological vertebral fractures | Hussien El-Maghraby | L-34 |
| 08:40-08:50 | The Dynamic Interspinous U implant «Coflex» in the Treatment of the Degenerative Lumbar Spine Diseases | Alexander Levshyn | L-35 |
| 08:50-09:00 | Interspinous Process Distraction Devices for the treatment of multilevel degenerative lumbar spinal stenosis | George Roumeliotis | L-36 |
| 09:00-09:10 | Foraminal decompression at patients with cervical radiculopathy and radiculomyelopathy | Konstantin Gordienko | L-37 |
| 09:10-09:15 | Discussion | | |
| | **Panel 3-Less Invasiv 1** | **Howard S An, Robert Hensinger** | |
| 09:15-09:25 | Lumbar fusion gentle to other segments | Sadaaki Nakai | L-38 |
| 09:25-09:35 | Combining Trans-Sacral, Lateral MIS, and Percutaneous Pedicle Screw Instrumentation in the Lumbar and Sacral Spine | Burak Ozgur | L-39 |
| 09:35-09:45 | The European Multicenter Trial for the Evaluation of the Safety and Efficacy of the GOLIF Spinal Instrumentation | Christof Birkenmaier | L-40 |
| 09:45-09:55 | Pedicle screw fixation under navigation guidance based on O-arm | Jin Sung Kim | L-41 |
| 09:55-10:00 | Discussion | | |
| 10:00-10:20 | ***Coffee Break*** | | |

| | | | |
|---|---|---|---|
| | **Panel 4-Less Invasiv 2** | **Bambang Darwono, Nils Haberland** | |
| 10:20-10:30 | Anatomy of triangular safe zone applied to posterolateral percutaneous procedures | Pil-Sun Choi | L-42 |
| 10:30-10:40 | Percuataneous Vertebroplasty - New treatment for osteoporotic fractures using indiginous instrumentation.AB needle | Arvind Bhave | L-43 |
| 10:40-10:50 | Clinical evaluation and experience of IVEP in Vertebral Compression Fracture | Shing-Sheng Wu | L-44 |
| 10:50-11:00 | Cervical multilevel decompressive fenestration: a new surgical technique for cervical spondylotic myelopathy | Cumhur Kilincer | L-45 |
| 11:00-11:10 | Microforaminotomy: A new surgical technique for lumbar root decompression | Cumhur Kilincer | L-46 |
| 11:10-11:20 | Spongioplasty a new Percutaneous Method - Technique, Indications and Results | Nils Haberland | L-47 |
| 11:20-11:25 | Discussion | | |
| | **Master Lectures** | **John Chiu, Koichi Sairyo** | |
| 11:25-11:40 | Percutaneus kyphoplasty: Sun Yat-sen University experience in Guangzhou ,China | Zheng Zhaomin | ML-10 |
| 11:40-11:55 | The Lateral Minimally Invasive Approach to the Lumbar Spine, One More Tool for the Spine Surgeon | Burak Ozgur | ML-11 |
| 11:55-12:10 | Minimally invasive surgery for the lumbar spondylolysis | Koichi Sairyo | ML-12 |
| 12:10-12:25 | Osteoporotic vertebral body compression: What is the best treatment technic? | Mehmet Zileli | ML-13 |
| 12:25-12:30 | Discussion | | |
| 12:30-13:30 | ***Lunch*** | | |
| | **Program Lectures** | **Murat Erguven, Altay Sencer** | |
| 13:30-13:40 | Kypoplasty | Altay Sencer | L-48 |
| 13:40-13:50 | Balloon Kyphoplasty in traumatic thoracolumbar fractures | Cumhur Kilincer | L-49 |
| 13:50-14:00 | Diagnostics of the lateral recess stenosis | Artem Skidanov | L-50 |
| 14:00-14:10 | Radiofrequency Thermocoagulation of Ganglion Impar in the Management of Coccydynia: Preliminary Results | Serdar Kabatas | L-51 |
| 14:10-14:20 | Postero-lateral approach for anteriorly located C2 tumors: Report of 2 cases | Cumhur Kilincer | L-52 |
| 14:20-14:25 | Discussion | | |

| | | | |
|---|---|---|---|
| | **Master Lecture** | **Sadaaki Nakai, Anthony Yeung** | |
| 14:25-14:40 | Posterior Lateral Thoracic Endoscopic Microdiscectomy with GPS System | John Chiu | ML-14 |
| 14:40-14:55 | Minimally invasive endoscopic spinal surgery in the management of pyogenic spinal infection | Akira Dezawa | ML-15 |
| 14:55-15:10 | The Transvertebral Herniotomy and its Expansive Indication | Sadaaki Nakai | ML-16 |
| 15:10-15:15 | Discussion | | |
| | **Master Lecture** | **Akira Dezawa, Lester Wilson** | |
| 15:15-15:30 | Identifying the pain generators in the spine, the efficacy of endoscopic spinal surgery | Anthony Yeung | ML-17 |
| 15:30-15:45 | The New Technique for the treatment of Osteoporotic Vertebral Fractures | Bambang Darwono | ML-18 |
| 15:45-16:00 | New approaches at minimal invasive spinal techniques | Vladimir Radchenko | ML-19 |
| 16:00-16:05 | Discussion | | |
| 16:05-16:25 | ***Coffee Break*** | | |

| | | | |
|---|---|---|---|
| | **Panel 5 - Intradiscal Therapies and Pain Management** | **Elvan Erhan, Cumhur Kilincer** | |
| 16:25-16:35 | Minimally Invasive Procedures in DDD - Classification on Pain Generator: Intrinsic and Extrinsic | Pil-Sun Choi | L-53 |
| 16:35-16:45 | Epidural steroid injections for spinal pain | Elvan Erhan | L-54 |
| 16:45-16:55 | A novel combination of facet joint injection and sural block for low back pain and sciatica | Figen Yagmur Aslan | L-55 |
| 16:55-17:05 | Foraminal Endoscopic Spine Surgery For Painful Degenerative Conditions of the Lumbar Spine: Focus on Endoscopic Decompression of Lateral recess stenosis | Anthony Yeung | L-56 |
| 17:05-17:15 | Pain Management and Intradiscal Therapies | Halil Algan | L-57 |
| 17:15-17:25 | Pulse radiofrequency applications on DRGs with PASHA-Cath - lumbar and cervical | Nurettin Luleci | L-58 |
| 17:25-17:35 | The Epidural Cocktail for management of Lumbar Disc Bulge | Mohamed Mohi Eldin | L-59 |
| 17:35-17:40 | Discussion | | |

| | | | |
|---|---|---|---|
| | **Program Lectures** | **Figen Yagmur Aslan, Mohamed Mohi Eldin** | |
| 17:40-17:50 | A Novel technique of microsurgical approach through laminofacet articular junction for Lumbar Disc herniation (Hole Approach), video presentation | Figen Yagmur Aslan | L-60 |
| 17:50-18:00 | A Novel technigue of microsurgical approach trough laminofacet articular junction for foraminal stenosis and spondylolisthesis (Hole Approach), video presentation | Figen Yagmur Aslan | L-61 |
| 18:00-18:10 | "Percutaneous automatic discectomy of cervical and lumbar spine" | Konstantyn Popsuishapka | L-62 |
| 18:10-18:20 | Coflex- Augmented Lumbar Microdecompression / Microlaminectomy, (Comparative Pilot Study) | Mohamed Mohi Eldin | L-63 |
| 18:20-18:30 | Coflex Dynamic Interlaminar-Interspinous Distraction Stabilization Device for Lumbar Degenerative Diseases (Initial Experience) | Mohamed Mohi Eldin | L-64 |
| 18:30-18:40 | Cervical Percutaneous Nucleotomy | Michael Schubert | L-65 |
| 18:40-18:50 | Percutaneous laser disk decompression in comparasion with microdiscectomy | Robert Saftic | L-66 |
| 18:50-19:00 | Correlation between Preoperative Imaging Studies and Post-Operative Results In Lumbar Canal Stenosis - A Prospective Study | Vijay Goni | L-67 |
| 19:00-19:10 | Integrated Outcome Assessment after Anterior Cervical Discectomy, Fusion (ACDF) with autograft and Plating in cervical spodylomyelopathy | Vijay Goni | L-68 |
| 19:10-19:15 | Discussion | | |
| 19:15-19:20 | ***Closing Lectures*** | Tolgay Satana | |

# *Chairpersons*

**PD Dr. med. Hansjšrg Leu**
Spezialarzt FMH für Orthopädische Chirurgie, insbes. Wirbelsäulen-Chirurgie
Toblerstrasse 51, CH-8044 Zürich web: http://www.medindex.ch/hansjoerg.leu
Tel. : 043 268 28 00 Natel : 079 227 19 45
Fax : 043 268 28 01 e-mail : bethania-spine@bluewin.ch
EAN : 7601000229434 KSK : N 3033 01 SUVA : 35-75205 RA1

## Curriculum Vitae

Date of birth January 5, 1954, Zurich/Switzerland

Studies

1979 Swiss Federal Examination, Medical Degree

1993 Habilitation/Venia Legendi as Private Docent for Orthop. Surgery, Med. Faculty, Zurich University

## Professional Activities

1980/1982 Department for General Surgery and Traumatology, Aargovian Cantonal Hospital, Aarau/ Switzerland.
Chairman: Prof.Dr.F.Deucher

1982/1985 Sct. for Orthopaedics, Thurgovian Cant. Hospital, Frauenfeld/Switzerland. Chief: Dr.U.Romer

1985/1995 Department for Orthopaedic Surgery Balgrist, Medical School, University of Zurich/Switzerland
Chairman : Prof. Dr. A.Schreiber

1988 Speciality Degree in Orthopaedic Surgery FMH

1989 - 1995 Clinical Lecturer and Senior Clinician, Balgrist Univ.Clinic

since 1993 Private Docent in Orthopaedics with instructional duties

1994-2000 PD-Representative for Orthopaedics, Faculty Group of Surgical Disciplines, University of Zurich/Switzerland

1992 - 31.3.1995 Senior Surgeon for Spinal Surgery, Balgrist Univ. Clinic Zurich

4.1995 – 10.2004 Consultant Orthop. Surgeon, Neumunster Hospital Zurich since 10/2004
Consultant Orthopaedic Spine Surgeon, Bethania Clinicum
Bethania Spine Base, Zurich, Switzerland

## Grants & merits

1991 ASG-Fellowship of the Austro/Swiss/German Orthopaedic Societies (ASG-Travelling Studies GB/USA 1992)

1992 Georg-Schmorl Award by the German Society for Spine Research, Frankfurt/Germany

2002 Doctor honoris causa, Sytenko Institute, Medical Faculty, University of Charkov, Ukraine

## Memberships

numerous memberships in national and international spine Societies

- International Society for Minimal Intervention in Spinal Surgery (ISMISS, since 1990)
  President in charge for 2008/2011

**Family** married since 1985 to Jutta-Maria, born Überle, 3 children
(Christoph 1986, Martin 1988, Isabelle 1990)

Zürich, February 28, 2009

## CURRICULUM VITAE

## MEHMET ZİLELİ, M.D.

Dr.Mehmet Zileli is the Professor and Head of the Neurosurgery Department in Ege University, Izmir, Turkey. He is a faculty member since 1989.

Between 1987-1988 he has worked as a Research Fellow in the Dept of Neurosurgery, University of Erlangen-Nürnberg, Germany (Prof.Johannes Schramm).

He is the founder and first president of the Spine Section of Turkish Neurosurgical Association, (1995-1999), First Vise President of the World Spine Society (2007-2008), President of the Turkish Neurosurgical Society (2006-2008), and the Vise President of the World Spinal Column Society since 2009, member of many national (9) and international (14) societies. He has been the program chairman of the World Spine IV Meeting (2007) which was held in Istanbul, Chairman of the 6th Black Sea Neurosurgical Congress (Istanbul, 2009). He is the Chairman of the 9th Asian Congress of Neurological Surgeons (ACNS), which will be held in 2012, in Istanbul, Turkey.

He has important contributions to education and training in spine surgery in Turkey. Since 1997 he organizes hands-on practical courses on spine surgery, and has organized a cadaver course in 2003 and 2005 in collobora-tion with Cleveland Clinic, USA and World Spine Society. He is the chief of a spine fellowship program that served many national and international fellows. He has also been the host of the “Travelling Fellowship of Spine Society of Europe” in 2002, 2003 and 2004.

He is the author or co-author of 45 international, and 70 national scientific papers, editor of 4 books, author of 13 international book chapters and 72 national book chapters. He has presented 202 papers or conferences in international meetings and 263 in national meetings.

He speaks English and German. He is merried, and father of two children

## CURRICULUM VITAE Christof Birkenmaier, MD

Orthopedic, Trauma & General Surgeon
Head of Spine Team and of Osteology Team
Department of Orthopedic Surgery,Grosshadern Medical Center, University of Munich
Marchioninistr. 15, D - 81377 Munich

### CLINICAL POSITIONS

2006 – cont.
Faculty, Dept. of Orthopedic Surgery, Großhadern Medical Center, University of Munich
2004 – 2006
Junior Faculty, Dept. of Orthopedic Surgery, Großhadern Medical Center, University of Munich

| | |
|---|---|
| 2001 - 2004 | Resident, Dept. of Orthopedic Surgery, Großhadern Medical Center, University of Munich |
| 1999 - 2001 | Resident, Dept. of Orthopedic Surgery, Medical Center rechts der Isar, Technical University Munich |
| 1995 - 1998 | Resident, Dept. of Surgery, Medical Center rechts der Isar, TU Munich |
| 1993 - 1995 | Resident, Dept. of Surgery, University of California, San Francisco, CA |
| 1989 - 1990 | House Officer, Departments of Orthopedics and General Surgery, Royal Free Hospital, London, UK |

### RESEARCH

| | |
|---|---|
| start 2009 | European Multicenter Trial for “Guided Oblique Lumbar Interbody Fixation” (GO-LIF) |
| 2006 - ongoing | Study of Epidural Pain Medications in a Fibroblast Cell Culture Modell, B. Braun Foundation research grant |
| 2006 - 2010 | Characterization of Cryolesions Used in Interventional Pain Therapy |
| 2004 - 2006 | Randomized Placebo-Controlled Multicenter Trial on the Efficacy of the Racz Epidural Catheter Therapy |
| 2002 - 2006 | Clinical Trial on Percutaneous Cryodenervation of Lumbar Facet Joints |
| 1990 - 1993 | Postdoctoral Research Fellowship at the Department of Surgery, University of California, San Francisco, CA, USA |

### EDUCATION

| | |
|---|---|
| 1982 - 1989 | MD at the University of the Saarland, Homburg, Germany |

### PROFESSIONAL LICENSES

| | |
|---|---|
| 2008, Oktober | Orthopedic Traumatology Board Certfication – M. Board of Bavaria |
| 2004, February | Orthopedic Board Certification - Medical Board of Bavaria |
| 2000, May | Surgical Board Certification - Medical Board of Bavaria |
| 1994, October | California Medical License |
| 1992 | German Medical License |

### PROFESSIONAL SOCIETIES

| | |
|---|---|
| SSE (EuroSpine) | member since 2009 |
| AOSPINE | member since 2005 |
| DGOOC | Deutsche Gesellschaft für Orthopädie & Orthopädische Chirurgie |
| ISMISS | International Society for Minimal Intervention in Spinal Surgery |

FELLOWSHIPS

| | |
|---|---|
| June 2009 | AO Spine Fellow at the Centre For Spinal Studies & Surgery, University Hospital, Queen’s Medical Centre, Nottingham, UK |

**Burak M. Ozgur MD**
Cedars-Sinai Medical Center Department of Neurosurgery
8631 W. Third Street, Suite 800E Los Angeles, CA. 90048
Office #: (310) 423-4259 - Office #: (310) 423-7900 - Fax #: (310) 423-0810
bozgur@gmail.com

**EMPLOYMENT**

Director of Minimally Invasive Spine Surgery Assistant Professor of NeurosurgeryDe partment of Neurosurgery Cedars-Sinai Medical Center October 2007 - present

University of California, Irvine Medical Center, Department of Neurological Surgery, Assistant Professor of Clinical Neurosurgery, Director of Spinal Neurosurgery, Co-Director of the Multidisciplinary Spine Program
July 2006 – October 2007

**HOSPITAL PRIVILEGES**

Cedars-Sinai Medical Center
Los Angeles, California

**EDUCATION**

University of California, San Diego Medical Center, Neurosurgery Chief Resident
June 2005 – June 2006
University of California, San Diego Medical Center, Neurosurgery Spine Fellowship
July 2004 – December 2004: Neurosurgery Spine (Dr. LF Marshall, Dr. WR Taylor)
January 2005 – June 2005: Orthopedic Spine (Dr. SR Garfin, Dr. C. Kim)
University of California, San Diego Medical Center
Neurosurgery Residency
June 2000 – June 2005
University of California, San Diego Medical Center
General Surgery Internship
June 1999 - June 2000
University of Vermont
College of Medicine, Class of 1999
MD degree awarded May 1999
University of California, Irvine
Biological Sciences major
Bachelor of Science degree 1994

# CURRICULUM VITAE
## Dr. med. Stefan Hellinger

Geb. 16.10.1962
German

Present position: Orthopaedic surgeon in privat practice and as consultant in Isar Klinik
Spec.: Spine and jointsurgery, Rheumatology, Pain therapy

Prof. Address: Windenmacherstr.2
80333 München

Prof. Qualifications: 1993 MD for medicine Universität Erlangen

Postgrad. Qualifications:

| | |
|---|---|
| 01/1994 - | Intern at surgical departement |
| 06/1994 | Kreiskrankenhaus Auerbach. |
| 07/.1994 - | Resident surgical department des StädtischenKrankenhaus Rothenburg o.d.T. |
| 07/1995 - | Resident in orthopaedic practice |
| 09/1995 | in Munich |
| 10/1995- | Resident in der Orthopädischen Abteilung des |
| 03/2000 | Kreiskrankenhaus Rheinfelden |
| 10/1999 | certification as orthopaedic surgeon |
| 04/2000- | Staff surgeon Orthopädischen Abteilung |
| 12/2000 | des Dreifaltigkeitshospital Lippstadt |
| 02/2001 | Degree for special orthopaedic surgery |
| 01/2001- | different Fellowships, |
| 06/2001 | spine fellow Zurich, Schulthess Clinic Prof. Grob |
| since07/2001 | Orthopaedic and spine surgeon in own practice and as consultant for the Isar clinic munich<br>sprec. on spine surgery, development of different minimal invasive procedures, spinal endoscopy |
| 2002 | Director of Institute for clinical research, consulting and expertise |

München, 11.11.08

**Wolfgang RAUSCHNING, M.D.,** Ph.D., born: 4. June 1938, Zinten, Germany
Department of Orthopaedic Surgery
Academic University Hospital
S - 751 85 UPPSALA, Sweden
Phone: (+46) 8 - 594 80169
Fax: (+46) 8 - 592 56128
e-mail: rauschning@quicknet.se

## EDUCATION, TRAINING and DEGREES:

| | |
|---|---|
| 1958 - 1964 | Studies at the Faculty of Medicine, Christian Albrecht University of Kiel, Germany |
| 1961 | B.Sc., Christian Albrecht University of Kiel, Germany |
| 1964 | M.D. Diploma, Christian Albrecht University of Kiel, Germany |
| 1964 | Doctorate Degree at Christian Albrecht University of Kiel (Grade: Magna cum Laude) |
| 1964 - 1967 | Internships in Internal Medicine, General Surgery, Gynecology (Western Germany) |
| 1967 | Certification by Licensure (licentia practicandi) in West Germany |
| 1967 | Permanent move to Sweden, Marriage to the former Birgitta Andersson, Stockholm |
| 1967 - 1969 | Residency in General Surgery, Kristinehamn, Sweden |
| 1969 | Certification by Licensure (licentia practicandi) in Sweden |
| 1970 - 1972 | Residency in Orthopaedic Surgery, Karlstad, Sweden |
| 1973 - 1974 | Residency in Orthopaedic Surgery, Academis University Hospital, Uppsala, Sweden |
| 1974 | Certified Specialist in General Surgery |
| 1975 | Specialist in Orthopaedic Surgery. Swedish Citizenship |
| 1976 - 1980 | Consultant Surgeon in Rehabilitation Medicine, Mälargården, Sigtuna |
| 1979 | Doctorate Degree at Uppsala University (equivalent to Ph.D.) |
| 1980 | Associate Professor at the Faculty of Medicine, Uppsala University |
| 1980 - 1983 | Visiting Research Associate at the University of Florida, Miami (Jackson Memorial Hospital and Mount Sinai Medical Center, Miami) |
| 1983 | Visiting Research Profesor, Medical College of Wisconsin, Milwaukee |
| 1983 - 1984 | Visiting Research Professor, Leo Rigler Center for Radiological Sciences, Dept of Radiology, UCLA |
| 1985 - 1988 | Associate Teaching Professor, Orthopaedic Surgery, Uppsala University |
| 1986 - 1987 | Co-Investigator and Consultant, “The Brain Mapping Project” Dept. of Neurosciences, University of California, San Diego |
| 1987 - present | Visiting Professor and Member of the Computer Graphics Committee, Department of Biologi cal Structure, University of Washington School of Medicine, Seattle |
| 1988 - 1994 | Research Associate, The Swedish Medical Research Council, Stockholm |
| 1994 - present | University Lecturer in Orthopaedic Surgery, Faculty of Medicine, Uppsala University and Uni versity Professor in Clinical and Applied Anatomy and Pathology |

**Daniel Gastambide, MD**

Nationality : French
Was a resident in Paris.
Medical doctor.
Orthopedic surgeon.
Chief of orthopedic surgery department in Blois.

Began private practice in Paris in 1992 (spine surgery 95%)
Is a founding member of the Group for Study of Intervertebral Approaches GIEDA INTER RACHIS: Groupe International d'Etude Des Abords INTERvertébraux du RACHIS and took part in the organization of its 22 annual congresses since 1988 (Blois, Brussels, Bordeaux, Paris, Lyon).
Was the president of this group in 2002.
Is the delegate for the www.gieda.com internet site and is the treasurer of this scientific association.
Is a member of ISMISS since 1990, French delegate, member of SOFCOT, SICOT, IITS, NASS, IMLAS.
2010 president of IITS (conjoined with the WCMISST congress in Las Vegas from May 31-June 4).
Multiple presentations on minimal invasive spine surgery.

## CURRICULUM VITAE

### PERSONAL INFORMATION:

| | |
|---|---|
| Full Name | Sebastian Ruetten, MD |
| Office | Department of Spine Surgery and Pain Therapy<br>Center for Orthopaedics and Traumatology<br>St. Anna-Hospital Herne<br>Hospitalstraße 19<br>44649 Herne<br>Germany |
| Date of Birth | April 22, 1968 |

### PROFESSIONAL HISTORY:

| | |
|---|---|
| 1993 - 1995 | Department of Orthopaedics, University of Bochum, St. Josef-Hospital Bochum, Germany<br>Director: Juergen Kraemer, MD, Prof |
| 1995 - 1996 | Department of Orthopaedics, University of Bochum, St. Anna-Hospital Herne, Germany<br>Director: Maurice Arcq, MD, Prof |
| 1997 | Department of Surgery, St. Marien-Hospital Gelsenkirchen-Buer, Germany<br>Director: Johannes Loehnert, MD |
| 1998 - 2000 | Department of Orthopaedics, University of Bochum, St. Anna-Hospital Herne, Germany<br>Director: Maurice Arcq, MD, Prof |
| 1998 - 2000 | Medical Head of the Center for Ambulant Rehabilitation “Come Back”, Gelsenkirchen, Germany |
| 02/2000 – 12/2004 | Clinic for Orthopaedics, University of Witten/Herdecke, St. Anna-Hospital Herne, Germany<br>Director: Georgios Godolias, MD, Prof |
| 01/2002 | Founder and Head of the Department of Spine Surgery and Pain Therapy, Clinic for Orthopaedics, University of Witten/Herdecke, St. Anna-Hospital Herne, Germany |
| since 01/2005 | Head of the Department of Spine Surgery and Pain Therapy at the newly founded Center for Orthopaedics and Traumatology, St. Anna-Hospital Herne, University of Witten/Herdecke, Germany<br>Assistant Director of the Center for Orthopaedics and Traumatology, St. Anna-Hospital Herne, University of Witten/Herdecke, Germany |

## CURRICULUM VITAE

## PERSONAL INFORMATION:


| | |
|---|---|
| Full Name | Semih Özdemir, MD |
| Office | Department of Spine Surgery and Pain Therapy<br>Center for Orthopaedics and Traumatology<br>St. Anna-Hospital Herne<br>Hospitalstraße 19<br>44649 Herne<br>Germany |
| Date of Birth | December 30, 1977 |


PROFESSIONAL HISTORY:

| | |
|---|---|
| 1998-2004 | Faculty of Medicine at the University of Bochum, Germany |
| 2005-today | Center for Orthopaedics and Traumatology, St. Anna-Hospital Herne, University of Witten/Herdecke, Germany<br>Member of the Department of Spine Surgery and Pain Therapy at the Center for Orthopaedics and Traumatology, St. Anna-Hospital Herne, University of Witten/Herdecke, Germany |

## CURRICULUM VITAE

## JAE-YOON CHUNG.M.D., Ph. D.

**OFFICE ADDRESS AND TELEPHONE**

Department of Orthopedic Surgery Chonnam University Hospital,

Hakdong-8, Gwangju, 501-757,Korea

Tel: 82-62- 227-1640, 220-6332 - Fax: 82-62-225-7794

E : jychung@chonnam.ac.kr

**BIRTH DATE**

February 7th, 1950

**PLACE of BIRTH** Gwangju, Korea

**EDUCATION**

1974. 2. M.B., M.D. Chonnam University Medical School

1977. 2. M.S. Chonnam University Graduate School

1983. 8 Ph. D. Chonnam University Graduate School

**POSTDOCTORAL TRAINING**

1974.3-1975.2 Internship

Chonnam University Hospital

Gwangju, Korea 1975.3.-1979.2

Resident, Orthopedic Surgery

Chonnam University Hospital Gwangju, Korea

# CURRICULUM VITAE

## Zheng Zhaomin, M.D. Ph.D.

**OFFICE ADDRESS**

Department of Spine Surgery, The First Affiliated Hospital, Sun Yat-sen University

phone: 0086-13925187872 fax: 8620-87332150 E-mail: zhengzm1@163.com

## FACULTY/HOSPITAL APPOINTMENTS

2005-Present: Professor & Head, Dept. of Spine Surgery, The First Affiliated Hospital, Sun Yat-sen University, Guangzhou, China

1998-2005: Associate professor, Dept. of Orthopedics, The Second Affiliated Hospital, Sun Yat-sen University, Guangzhou, China

1989-1991: Resident, Dept. of Surgery, the Second Affiliated Hospital, Henan Medical University, Henan, China

## TRAINING

Minimally invasive spine surgery, 6 months in USA, 2000

Clinical fellowship and research on spine surgery in Orthopedic Department of Hong Kong University, 2004

AO Spine Visiting prof., University of California, Los Angeles, USA, 2008.9-11

SRS global outreach traveling fellowship, Hospital for Special Surgery, New York, USA, 2010.1-2

## AWARDS & HONORS

Maurice E. Müller/SICOT Award, by the International Society of Orthopaedic Surgery and Traumatology(SICOT), 2008.8

## MEMBERSHIP IN PROFESSIONAL SOCIETIES

Committee member of the International Society for Minimal Intervention in Spinal Surgery (ISMISS)

Director of the Pacific & Asian Society of Minimally Invasive Spine Surgery (PASMISS)

Lecturer of the China Chapter, AO Spine International

## Curriculum Vitae

**FUJIO ITO M.D**
President of Aichi Spine institute
Guest professor of spine surgery, department of neurosurgery, Fujita Health University

Office; Aichi Spine institute
41 Gouhigasi, Takao, Fuso-cho, Niwa-gun,
Aichi, Japan
480-0102

Born: Aichi-prefecture Japan(1946)

M.D. Degree: Medical Doctor(1974)

Internship: Medical School of Nagoya University(1970-1971)

Residency: Nagoya National Hospital, Neurology(1971-1972)

## Dr. Tolgay Şatana

**Ama•** Ortopedi ve Travmatoloji Uzmanlığı

**Deneyim** Ortopedi ve Travmatoloji Uzmani 22.10.2008-halen
Çamlık Hastanesi Bakırköy Istanbul
Ortopedi ve Travmatoloji Uzmani 1.4.2008-14.10.2008

Acıbadem Beylikdüzü Tip Merkezi, Istanbul
Ortopedi ve Travmatoloji Uzmani 1.12.2004-1.4.2008
Medart Tip Merkezi, Ankara
Ortopedi ve Travmatoloji Uzmanı
15.4.2004-1.12.2004
ODTU Saglik Merkezi, Ankara
Ortopedi ve Travmatoloji Uzmanı
24.3.2002-15.4.2004
Ankara Eğitim ve Araştırma Hastanesi Ulus Semt Polikliniği
Medart Tip Merkezi (Yarı zamanlı Eylül 2003), Ankara
Ortopedi ve Travmatoloji Uzmanı
15.1.2002-17.12.2002
SEV Gaziantep Amerikan Hastanesi, Gaziantep
•Ortopedi ve Travmatoloji Uzmanı Aralık 2001-5.3.2002
S.B. Gaziantep Devlet Hastanesi Gaziantep
•Ortopedi ve Travmatoloji Uzmanı
Ağustos 1999- Aralık 2000
S.B. Etimesgut Devlet Hastanesi Ankara
•Ortopedi ve Travmatoloji Uzmanı
Mayıs 1998- Temmuz 1999
Mareşal Çakmak Askeri Hastanesi Erzurum
•Ortopedi ve Travmatoloji Uzmanı Ağustos 1997- Mart 1998
S.B. Etimesgut Hastanesi Ankara
•Hükümet Tabibi
Eylül 1991- Haziran 1992
S.B. Tuzluca Merkez Sağlık Ocağı Iğdır

**Anthony T. Yeung, M.D.**
**Curriculum Vitae**

Arizona Institute for Minimally Invasive Spine Care
Arizona Orthopedic Surgeons
Squaw Peak Surgical Facility, Medical Director
1635 East Myrtle Avenue – Suite 400 (602) 944-2900
Phoenix, Arizona 85020

| | | |
|---|---|---|
| | Wuchow, China | December 12, 1940 |
| **B.S. Degree:** | University of Arizona – Tucson<br>Zoology – Chemistry | 1965 |
| **M.D. Degree:** | University of New Mexico School of Medicine | 1970 |
| **Internship:** | Good Samaritan Hospital<br>Phoenix, Arizona | 1970 - 71 |
| **Residency:** | Maricopa County General Hospital<br>Phoenix, Arizona | |
| | General Surgery | 1971 – 72 |
| | Orthopedic Surgery | 1973 – 75 |
| **Military Service:** | LCDR, Medical Corp. – U.S. Navy<br>Naval Regional Medical Center<br>Subic Bay, Philippines | 1976 – 78 |
| | Chief of Orthopedics | 1977 – 78 |
| **Private Practice:** | The Orthopedic Clinic – Associate<br>Phoenix, Arizona | 1978 – 88 |
| | Arizona Orthopedic Surgeons<br>Phoenix, Arizona | 1989 – Present |
| | Arizona Institute for Minimally Invasive Spine Care<br>Phoenix, Arizona | 2001 – Present |
| **Board Certified** | **American Board of Orthopedic Surgery** | **1977** |
| **Academic Appointments:** | | |
| | Phoenix Orthopedic Residency Program<br>Consultant and Clinical Instructor | 1978 – 99 |
| | Arizona Crippled Children Hospital/<br>Children's Rehabilitative Services<br>Consultant and Clinical Instructor<br>Cerebral Palsy Clinic | 1978 – 99 |
| | Good Samaritan Family Practice<br>Residency Program<br>Consultant and Preceptor | 1979 – 99 |
| | Voluntary Clinical Associate Professor<br>University of California San Diego School of Medicine<br>Department of Orthopedics | 2002-Present |

## CURRICULUM VITAE
## PERSONAL INFORMATION:


| | |
|---|---|
| Full Name | Patrick Hahn, MD |
| Office | Department of Spine Surgery and Pain Therapy<br>Center for Orthopaedics and Traumatology<br>St. Anna-Hospital Herne<br>Hospitalstraße 19<br>44649 Herne<br>Germany |
| Date of Birth | Mai 04, 1972 |


## PROFESSIONAL HISTORY:

| | |
|---|---|
| 1993-2000 | Faculty of Medicine at the University of Saarland, Germany |
| 2001 - 2003 | Center for Trauma-, Hand- und Reconstructive Surgery, Johann Wolfgang Goethe-Universität, Frankfurt am Main<br>Director: Ingo Marzi, MD, Prof |
| Since 2003 | Center for Orthopaedics and Traumatology, St. Anna-Hospital Herne, University of Witten/Herdecke, Germany<br>Director: Georgios Godolias, MD, Prof |
| 2008 | Practice for Chirotherapie |
| 2009 | Practice for Natural Medicine |
| 2009 | Practice for Akupunkture |

## Radchenko Vladimir Alexander, date of birth 1956, Ukraine

Head od Department of Spine surgery,

Vice-Director of Sytenko Institute of Spine and Joint Pathology,Kharkov,Ukraine

Professor of Orthopaedics and Traumathology,

Professor of Academia of Postgraduate Education,Kharkov

Merited Statesman of Science and Technique

Presidents Award of Science and Technique

**Parlaments Award**

### Work Experience

since 1979 – General Surgeon in Dneepropetrovsk clinic

1980-1984 Department of Orthopaedics and Traumatology, Emergency Hospital Dneeprodzerginsk

since 1984- Sytenko Institute of Spine and Joint Pathology – Department of Spine Surgery

### Spine Society

Ukrainian Society of Orthopaedics and Traumatology (vice-president)

International Society of Minimal Intervention in Spinal Surgery ISMISS (vice-president, European Branch secretary);

Society of Orthopedics and Traumatology SICOT (since 1994)

AO Spine International

## CURRICULUM VITAE

## Name: Halil Algan

**Address:** Acıbadem Hastanesi Ağrı tedavisi Bölümü
Acıbadem Tekin Sokak 8 Kadıköy
34718 Istanbul TURKEY
Tel: +90 (216) 544 4092
Cellular: +90 (532) 365 1899
Fax: +90 (216) 428 3441

**E-mail:** alganh@yahoo.com

### Birth Date and Place:

May 31, 1966 Izmir, Turkey

### Current Status:

Physician, Pain Management Department

### Education :

- MD., 1991 Ege University, School of Medicine, Izmir, Turkey
- Anesthesiology and Reanimation Specialist, 1997, Marmara University School of Medicine, Department of Anesthesiology and Reanimation, Istanbul, Turkey

Regional Anesthesia and Pain Management assistant, 1996, Thalwil Hospital, Zurich, Switzerland

Pain Management fellowship, 1997, Yale University School of Medicine, Yale Center for Pain Management, New Haven, CT, USA

Pain Management, 1997, HealthSouth Pain Management Services, Birmingham, AL, USA

Pain Management, 1998, HealthSouth Pain Management Services, Birmingham, AL, USA

Pain Management fellowship, 2000, HealthSouth Pain Management Services, Birmingham, AL, USA

### Professional Experience

- Marmara University Neurological Sciences Institute, Anesthesiology and Pain Management, 1997-1998
- Acibadem Healthcare Group Hospitals, Pain Management Departments, Department Head and Consultant, 1998-2004
- Founder and head of a Multidisciplinary Pain Clinic, 2004-2006
- Acibadem Healthcare Group Hospitals, Pain Management Departments, Department Head and Consultant, 2006-

**CURRICULUM VITAE (Howard S. An, M.D.)**

**OFFICE ADDRESS:** Rush University Medical Center
1725 W. Harrison St. Suite 1063 Chicago, Illinois 60612
phone: 312-243-4244 fax: 312-942-1516 E-mail: howard.an@roshortho.com

## EDUCATION:

1979 B.A. (chemistry), The College of Wooster, Wooster, OH
1982 M.D. The Medical College of Ohio, Toledo, OH

## POSTGRADUATE EDUCATION:

| | |
|---|---|
| 1982-1983 | Internship, Medical College of Ohio |
| 1983-1988 | Orthopaedic Residency, Medical College of Ohio |
| 1988-1989 | Spine Fellowship at Thomas Jefferson University Hospital and Pennsylvania Hospital (Rothman Institute), Philadelphia, PA |

## FACULTY APPOINTMENTS:

| | |
|---|---|
| 1989-1992: | Assistant Professor of Orthopaedic Surgery, Medical College of Wisconsin Milwaukee, WI |
| 1992-1997: | Associate Professor, Medical College of Wisconsin |
| 7/1997: | Professor of Orthopaedic Surgery with Tenure, Medical College of Wisconsin |
| 9/1/1997 -present: | Professor of Orthopaedic Surgery with Tenure, Rush Medical College, Chicago |
| 11/1997 -present: | The Morton International Endowed Chair. Dept. of Orthopaedic Surgery. Rush Medical College Chicago, Illinois |



**Robert N. Hensinger, M.D.**

William S. Smith Professor of Orthopaedic Surgery

1500 E. Medical Center Drive

2912 Taubman Center, Box 5328

Ann Arbor, MI 48109-5328

(734) 936-5715

rnh@med.umich.edu

## Education and Training

08/1952-06/1956 High School, St. Mary High School, Jackson, Michigan

09/1956 – 06/1960 Undergraduate, A.B., University of Michigan

09/1960 – 06/1964 Graduate, M.D., University of Michigan

## Postdoctoral Training:

7/1/64-6/30/65 Internship, University of Michigan (Surgery)
7165-6/30/66 Resident, University of Michigan, Assistant Resident in General Surgery
7/1/68-6/30/71 Resident, University of Michigan, Orthopaedic Surgery

## Postgraduate Training:

05/1972 Northwestern University, Chicago, Illinois, “Management of the Juvenile Amputee,” Prosthet ics-Orthotics

## Military Service:

Lieutenant, United States Navy; Submarine Medical Officer, New London, Connecticut, and Holy Lock, Scotland, 7/66-6/68

## Certification and Licensure:

American Board of Orthopaedic Surgery, 9/22/72

State of Michigan (No. 26445), 1964

Re-certified 7/7/92; valid until 12/31/06

Re-certified 6/23/05; valid until 12/31/16

Academic, Administrative and Clinical Appointments:

**Name: Aloysius Bambang Darwono**

**Sex:** Male

**Date of Birth:** 5 – 9 – 1948

**Place of Birth:** Magelang

**Present Address:** Orthopaedic Section of Pluit Hospital , Jl. Raya Pluit Selatan, Jakarta Utara

**E-mail:** bdarwono@hotmail.com

**PRESENT APPOINTMENT:** Senior Lecturer

**POSITION :**

1. Head of Orthopaedic Section of Pluit Hospital , Jl. Raya Pluit Selatan, Jakarta Utara
2. Head of Orthopaedic Section of Gading Pluit Hospital, Jl. Boulevard Timur Raya, Kelapa Gading, Jakarta

**ACADEMIC/PROFESSIONAL QUALIFICATIONS :**

| | |
|---|---|
| Medical Doctor | ( 1975 ) Private University of UNISSULA Semarang |
| General Surgeon | ( 1986 ) State University of Diponegoro Semarang |
| Orthopaedic Surgeon | ( 1990 ) State University of Indonesia Jakarta |
| Ph.D | ( 2000 ) State University of Gajah Mada Yogyakarta |

**TEACHING ASSIGMENTS**

Senior Lecturer Faculty of Medicine, The Veteran Pembangunan Nasional University since 2000

**BIOGRAPHY of JOHN C. CHIU, M.D., FRCS (U.S.) Medical Director**, **California Center for Minimally Invasive Spinal Surgery and California Spine Institute Medical Center**, 1001 Newbury Road, Thousand Oaks, CA 91320, chiu@spinecenter.com

Dr. John C. Chiu is a pioneer in the field of endoscopic spinal surgery. He is the President of California Spine Institute Medical Center and the founding chairman of American Academy of Minimally Invasive Spinal Surgery and Medicine (AAMISMS). With extensive experience in minimally invasive spine surgery (MISS), he is actively involved in MISS clinical research, development and education. He received a D.Sc. degree in surgical research on Tissue Modulation Technology and was appointed a Professor of Minimally Invasive Spinal Surgery in Neurosurgery, and subsequently as the Provost of the American International University and President, ISMISS/SICOT (International Society of Minimally Invasive Spinal Surgery) in January 2007. Dr. Chiu is an adjunct Professor in Spine Surgery, Orthopaedic Surgery Dept. Faculty of Medicine, both at Ain Shams University, Cairo, Egypt, and at Hunan Medical University of TCM, and a Clinical Professor, The First Affiliated Hospital of Hunan University of TCM, Changsha, Hunan, China.

Dr. Chiu was involved in micro vascular neurosurgery and microspine surgery, before dedicating his practice to the advancement of minimally invasive spinal surgery and endoscopic spine surgery. He has been involved in the development of robotic surgery, telesurgery, OR of the Future, tissue modulation technology including laser thermodiskoplasty, and the use of radiofrequency and bipolar technology. He is an active advocate of redefining the algorhythm for the treatment of degenerative spinal disorders and spinal segmental motion preservation with MISS. He has served as a spinal consultant to eight companies related to MISS products and digital technology. He also served on a spinal advisory committee of one of the largest health care insurance companies, and as a special advisor/consultant to a State Department of Labor and Work Force Development. Recently he conducted the first interactive live Webcast on endoscopic MISS, with nearly 1,000 global participants and viewed by 3,000, and participated in a global tele-video web conference involving 3 continents (UCLA, USA, North America; Bordeaux, France, Europe; Korea, Asia).

He is the Editor in Chief for "The Internet Journal of Minimally Invasive Spinal Technology" and is a co-editor of the textbook "Practice of Minimally Invasive Spinal Technique" (2000 and 2005 editions) and on the editorial board of the journals "Surgical Technology International" and the "Journal of Minimally Invasive Spine Technique," Dr. Chiu has authored numerous articles in peer review journal and 45 textbook chapters and other publications on MISS and related topics. He is a recipient of various honors and awards from professional societies, medical universities, and governmental entities, globally and in the US.

Dr. Chiu has lectured and performed spine surgeries throughout the world. He has held visiting professorships at universities worldwide and has served as course director for numerous spine surgery seminars and workshops both in the United States and abroad. He has written or presented over 800 papers (peer reviewed) at national and international scientific conferences, including North American Spine Society, American Academy of Neurological Surgeons, Congress of Neurological Surgeons, World Spine, World Congress of Neurosurgery, AAMISMS, ISMISS/SICOT and other meetings. He also has demonstrated and performed numerous live endoscopic spine surgeries at major medical centers and university hospitals around the world. His patients have included international VIP's, leading medical professionals (neurosurgeons, spine surgeons, and others), top government officials, generals and even a head of state.

He has been invited as a lecturer, visiting professor, chairman of various conferences and keynote speaker on endoscopic MISS in numerous university medical centers, and in numerous conferences in countries including China, Hong Kong, India, Iran, Korea, Singapore, Taiwan, England, France, Germany, Greece, Italy, Luxembourg, Spain, Switzerland, Russia, Ukraine, Israel, Jordan, the Kingdom of Saudi Arabia, Marrakesh, Morocco, United Arab Emirates, Egypt, Brazil, Colombia, Mexico, Venezuela, Uruguay and others. Internationally, Dr. Chiu also has served as the honorary President of the Mexican Minimally Invasive Spine Surgery and Orthopedic and Trauma Society, Co-chairman of the 1st Chinese International Minimally Invasive Spine Surgery Congress, MISS China, 2007 and others.

Born in Fukien China, he received his medical degree from Baylor University College of Medicine and Neurosurgical training at the Mayo School of Medicine. Further training and fellowship were undertaken at the State University of New York, University of Zurich and the University of Lund in Sweden. Dr. Chiu is certified by the American Board of Neurological Surgery. Has served as an advisor/consultant for American Medical Foundation for Peer Review and Education for major teaching hospitals and medical staff to establish proper peer review and credentialing process.

His outside interests include playing the Chinese classical musical instrument, Guzheng (Zither) and practice of martial arts and its philosophy, as a grand master in kung fu, ninjitsu, and jujitsu. He participated in the International Martial Arts Tournament, St. Petersburg, Russia and is the recipient of the Martial Arts Lifetime Achievement Award, and the Martial Arts Pioneer Award as well as other awards, and an invited speaker for the Humanitarian Award in Martial Arts, U.S.A. International Black Belt Hall of Fame.

## KOICHI SAIRYO

EDUCATION

| | |
|---|---|
| Dec. 8, 1994, | PhD degree, Medical Science<br>University of Tokushima, Tokushima, Japan |
| Mar. 31, 1988, | MD degree<br>University of Tokushima, Tokushima, Japan |

## BOARD CERTIFICATION IN JAPAN

| | |
|---|---|
| 1988 | National Board of Medical Doctor (physician) (registration #312233) |
| 1994 | Approved Orthopaedic Surgeon by Japanese Orthopaedic Association |
| 2003 | Board-certified spine surgeon (approved by the board of the Japanese Society for the Spine Surgery and Related Research) |
| 2008 | Board-certified endoscopic spine surgeon (approved by Japanese Orthopaedic Association) |

## PROFESSIONAL AND ACADEMIC EMPLOYMENT HISTORY

| | |
|---|---|
| April 1, 1992, | Resident, Department of Orthopedic Surgery, Health Insurance Naruto Hospital (until Sep 1995) |
| Oct. 15, 1995, | Visiting Scholar & Postdoctoral associate, Iowa Spine Research Center, Department of Biomedical Engineering, University of Iowa. |
| Mar. 19, 1997, | Clinical spine fellow, Department of Orthopedics, University of Tokushima, Japan |
| July 1, 1998, | Assistant Professor, Department of Orthopedics, University of Tokushima, Japan |
| Oct. 1, 1999- Dec. 2009 | Associate Professor, Department of Orthopedics, University of Tokushima, Japan |
| Sep. 1, 2003 | Sabbatical (until Dec. 31, 2005) |
| Sep. 1, 2003- Dec.200 | Visiting Scholar, Spine Research Center, Departments of Bioengineering and Orthopaedic Surgery, University of Toledo, Toledo, Ohio. |
| Jan. 1, 2010 - present | Associate Professor, University of Teikyo Mizonokuchi Hospital, Kanagawa, Japan |

## ALTAY SENCER

**Meslek :**

Hekim, Nöroşirürji uzmanı, öğretim üyesi

**Unvan :**

Doç. Dr.

**Konum :**

İ.Ü. İstanbul Tıp Fakültesi, Nöroşirürji Anabilim Dalı

**Doğum Yeri :** İstanbul

**Doğum Tarihi :** 02.12.1968

**Adres Bilgileri**

**Adres :** Ataköy 9.kısım A-4B D.122, 34158, İstanbul

**Telefon :** 0212 6311618 (iş) 0532 6835736 (mobil)

**Fax :** 0212 534 0252

**E-mail :** altayser@gmail.com, altayser@superonline.com

**Eğitim ve Kariyer Bilgileri**

**Eğitim :** Istanbul Sankt Georg Avusturya Lisesi

1979 – 1987 İ.Ü. İstanbul Tıp Fakültesi

1987 – 1993 İ.Ü. İstanbul Tıp Fakültesi, Nöroşirurji A.D.

1993 - 1999 (uzmanlık eğitimi)

**Yurt dışı Eğitim**

University of Washington, Dept. of Neurosurgery, Seattle, USA (Eylül-Aralık ‘98)

**Kariyer :** İ.Ü. İstanbul Tıp Fakültesi Nöroşirürji A.D.

Uzman 2000 -2009

Doçent 2009 - ……

## Curriculum Vitae

**Sadaaki Nakai M.D.**

Professor, Department of Orthopedic Surgery, Faculty of Medicine, Fujita Health University Toyoake-City, Aichi-Prefecture, Japan

**Present Appointment:** Department of Orthopedic Surgery

**Date of Birth:** September 4, 1947

**Education:** University of Keio, 1973

**Postgraduate Training:**

National Murayama Hospital, 1978

German Scoliosis Center in West Germany, 1981

National Murayama Hospital, 1983

Fujita Health University, 1987

Fujita Health University, Assistant Professor, 1991

Fujita Health University, Associate Professor, 1997

Fujita Health University, Professor, 2003

**Professional Societies and Association:**

Japanese Orthopedic Association, Member

Japan Spine Society, Councilor

Central Japan Orthopedic Surgery and Traumatology, Councilor

Japan Scoliosis Research Society, Secretary-General

Japanese Society for Minimally Invasive Orthopedic Surgery, Councilor

Japanese Spinal Instrumentation Society, Councilor

Japan Spinal Injury Society, Councilor

SICOT, Member

NASS(North American Spine Society), Member

**Anthony T. Yeung, M.D.**
**Curriculum Vitae**

Arizona Institute for Minimally Invasive Spine Care
Arizona Orthopedic Surgeons
Squaw Peak Surgical Facility, Medical Director
1635 East Myrtle Avenue – Suite 400 (602) 944-2900
Phoenix, Arizona 85020

| | | |
|---|---|---|
| **Born:** | Wuchow, China | December 12, 1940 |
| **B.S. Degree:** | University of Arizona – Tucson<br>Zoology – Chemistry | 1965 |
| **M.D. Degree:** | University of New Mexico School of Medicine | 1970 |
| **Internship:** | Good Samaritan Hospital<br>Phoenix, Arizona | 1970 - 71 |
| **Residency:** | Maricopa County General Hospital<br>Phoenix, Arizona | |
| | General Surgery | 1971 – 72 |
| | Orthopedic Surgery | 1973 – 75 |
| **Military Service:** | LCDR, Medical Corp. – U.S. Navy<br>Naval Regional Medical Center<br>Subic Bay, Philippines | 1976 – 78 |
| | Chief of Orthopedics | 1977 – 78 |
| **Private Practice:** | The Orthopedic Clinic – Associate<br>Phoenix, Arizona | 1978 – 88 |
| | Arizona Orthopedic Surgeons<br>Phoenix, Arizona | 1989 – Present |
| | Arizona Institute for Minimally Invasive Spine Care<br>Phoenix, Arizona | 2001 – Present |
| **Board Certified** | **American Board of Orthopedic Surgery** | **1977** |
| **Academic Appointments:** | | |
| | Phoenix Orthopedic Residency Program<br>Consultant and Clinical Instructor | 1978 – 99 |
| | Arizona Crippled Children Hospital/<br>Children's Rehabilitative Services<br>Consultant and Clinical Instructor<br>Cerebral Palsy Clinic | 1978 – 99 |
| | Good Samaritan Family Practice<br>Residency Program<br>Consultant and Preceptor | 1979 – 99 |
| | Voluntary Clinical Associate Professor<br>University of California San Diego School of Medicine<br>Department of Orthopedics | 2002-Present |

## CURRICULUM VITAE

**Name, Family name :** **Dezawa**
**Forename :** **Akira**
**Sex :** Male
**Date of birth:** 24 November 1951
**Place of birth:** Japan
**Marital status:** Married
**Nationality:** Japanese

Present address: Department of orthopaedic surgery,
University of Teikyo, Mizonokuchi hospital 3-8-3Mizonokuchi Takatsu-ku Kawasaki city Kanagawa 213 Japan
Phone 044-844-3333
FAX 044-844-2470
E-mail: adezawa@med.teikyo-u.ac.jp

### Education:

1974-1980 University of Chiba
Awarded the degree of medical doctor

1982-1986 Department of orthopaedic surgery, University of Chiba
Awarded the degree of PhD in spinal cord injury for a thesis entitled “Quantitative analysis of spinal cord injury using the isopotential spinal cord surface mapping “.work supervised by professor Shunichi Inoue.

### Work Experience

2006-present vice director Teikyo
University School of Medicine,Mizonokuchi hospital

2004-present professor Department of Orthopaedics ,Teikyo
University School of Medicine,Mizonokuchi hospital

1996-2004 Associated professor, Department of Orthopaedics ,Teikyo
University School of Medicine,Mizonokuchi hospital

1991-1996 Assistant professor Department of Orthopaedics,Teikyo
University

1988-1991 Manager of Chiba Ryoikucenter

1987-1988 Head of Orthopaedics National Yokohama Higashi Hospital

## Elvan Erhan, MD, FIPP

**Place of Birth:** Manisa, Turkey, Date of Birth: June 8, 1967

**Adres:** Department of Algology, Ege University, Faculty of Medicine, 35100, Izmir, Turkey

**E-mail:** elvanerhan@yahoo.com, elvan.erhan@ege.edu.tr

### Education:

1973-1978: Gazi Elementary School, Manisa

1978-1982: American Collegiate Institute, Izmir

1982-1985: Science High School, Ankara

1985-1991: Ege University, Faculty of Medicine, Izmir

**Work Experience:**

1992-1996: Ege University, Faculty of Medicine, Department of Anesthesiology and Reanimation (resident)

1996-2000: Ege University, Faculty of Medicine, Department of Anesthesiology and Reanimation, Department of Algology (specialist)

2000-2003: Ege University, Faculty of Medicine, Department of Anesthesiology and Reanimation, Department of Algology (Assistant Professor)

2003-2009: Ege University, Faculty of Medicine, Department of Anesthesiology and Reanimation, Department of Algology (Associate Professor)

2009 - : Ege University, Faculty of Medicine, Department of Anesthesiology and Reanimation, Department of Algology (Professor)

29/9/2007: World Institude of Pain (WIP) – Pain Practice Board Examination, Fellow of Interventional Pain Practice (FIPP)

2007: Turkish Society of Algology, Board Certificate

**Membership of Associations:** IASP (International Association for the Study of Pain), WIP (World Institute of Pain), Turkish Society of Anesthesiology, Turkish Society of Algology, Turkish Society of Regional Anesthesiology

She is the author of 18 international and 30 national scientific papers, author of 1 international book chapter and 12 national book chapters. She has presented and given talks in international (63) and national (55) scientific meetings. She is also reviewer or editorial board member of international (5) and national (3) scientific journals. She speaks English. She is married and has one daughter.

**Cumhur KILIN, ER, M.D., Ph.D.**

**ADRESSES**

Office Trakya University Medical Faculty

Department of Neurosurgery

22030 Edirne, Turkey

**E-mail:** ckilincer@trakya.edu.tr, ckilincer@hotmail.com

**Website**: http://ckilincer.trakya.edu.tr/index_eng.htm

**PHONE:** +90-284-2355798 Office, +90-532-5238064 Cellular

| | |
|---|---|
| **DATE OF BIRTH** | December 14, 1966 |
| **PLACE OF BIRTH** | Amasya Ç. Maden, Turkey |
| **MARITAL STATUS** | Married (with Mrs. Aysun KILINCER) |
| **CITIZENSHIP** | Republic Of Turkey |
| **EDUCATION** | Medical School<br>University of Istanbul, Faculty of Medicine, Istanbul, Turkey. M. D., 1983 - 1989 |

## Dr. Figen Yağmur ASLAN

### Education

1985- 1991:Akdeniz University (Antalya, Türkiye);General practitioner \ School of Medicine 1993 - 2001:Akdeniz University (Antalya, Türkiye);Medical Doctor \ School of Medicine, Specialist Training Programmeb of Neurosurgery

2001- 2008:: General Hospital Antalya, Türkiye; Neurosurgeon \ Department of Neurosurgery

**Mohamed M. Mohi Eldin**

Professor of Neurosurgery

Office: Department of Neurosurgery, Cairo

University Hospitals, Kasr El Aini, Cairo, Egypt.

Clinic: Arayes Buildings No.1, Sudan st., at the end of Ahmed Oraby St., Mohandseen, Giza, Egypt.

Telephones: Cell 0020127342964, Cell Clinic 0020123403690

Clinic & Fax 0020233022907

**Email:** mmohi63@yahoo.com,

**MyWeb:** http://cairo.academia.edu/MohamedMohiEldin

**Date:** February 2010.

**Full name:** Professor Mohamed M. Mohi Eldin El Basiony

**Short name:** Professor Mohamed Mohi Eldin , MB-BCH , M.Sc., MD

**Position/title:** Consultant Neurosurgeon/Professor in Neurosurgery and Spine.

**Nationality:** Egyptian.

**FIELD OF SPECIALIZATION:** Neurosurgery & Spine Consultant.

# Lectures

## Mehmet Ali Tumoz

He was born in Ankara in 1947. He graduated from Ankara University Medical Faculty in 1971. He gained the reputation of orthopaedic and traumatology specialist in 1981 after finishing the residency program at Ankara Numune Hospital 1st Orthopaedics and Traumatology Clinic. He worked as a staff and later associate chief in the same clinic. He became the chief of 2nd Orthopaedics and Traumatology Clinic in 1991. His practice specializes in the diagnosis of osteoarthritis and osteoporosis and their treatment. He is a member of Federation of Turkish Orthopedic Societies, SICOT, EFORT, European Hip Society, Turkish Arthroplasty Society and Turkish Spine Society. He is married and has 2 children.

# History of Minimal Invasive Spinal Surgery

*Mehmet Ali Tumoz*

Minimally invasive spinal procedures are currently being used effectively to treat a variety of commonly encountered degenerative conditions of the cervical, thoracic, and lumbar spine. Patients prefer minimally invasive techniques because such techniques reduce recovery times and provide cosmetic benefits. Reviewing the history of minimally invasive surgery helps us understand the advances in spine surgery.

The modern era of surgical endoscopy was initiated by the introduction of video-assisted endoscopic capabilities in the late 1970s and 1980s. Arthroscopy for the diagnosis and treatment of knee and shoulder pathologies grew and essentially replaced open techniques. The revolutionary growth of laparoscopic general surgery began in the late 1980s. Currently, laparoscopic approaches to the spine are being used for anterior lumbar spinal fusion.

The modern era of thoracoscopic surgery began in the early 1990s. Advances in technology and the addition of the video screen to standard endoscope led to video-assisted thoracic surgery. Thoracoscopic approaches are steadily gaining acceptance as efficient and safe methods of treating a variety of spinal disorders.

The pace of technological advancement has increased rapidly, and these developments have found application in the treatment of a number of spinal disorders. Improved imaging techniques for spinal image-guided systems and endoscopic spinal equipment have placed complex spine procedures on the verge of further advancement. These developments have led to surgical approaches to the spine that can result in less tissue trauma and, therefore, reduce a patient's postoperative pain and discomfort, shorten hospital stays, and allow a quicker return to activities of daily living. Complications such as iatrogenic instability or hastened degeneration at an adjacent level can potentially be reduced using these techniques by maintaining the integrity of normal anatomic tissue structures while limiting retraction-related injuries.



## Halil İbrahim Açar, MD

Department of Anatomy, Ankara University, Ankara, TURKEY

Halil İbrahim Açar was born August 3, 1978, Ankara. He was graduated from Ankara University Faculty of Medicine in 2001 and then he completed the anatomy residency program of Ankara University Faculty of Medicine, Department of Anatomy in 2002. His current position is instructor of anatomy in Ankara University, Department of Anatomy.

Dr. Açar has published more than 20 international papers and he is a member of the Turkish Society of Anatomy and Clinical Anatomy. His scientific fields of interest are surgical anatomy of upper extremity, abdominopelvic autonomic nerves anatomy and spinal cord neurovascular anatomy.

# Anatomy of the Lumbar Intervertebral Foramen

*Halil Ibrahim A ar, MD*

*Department of Anatomy, Ankara University, Faculty of Medicine, Ankara, Turkey*

Intervertebral foramen is a door between the spinal cord and periphery. This canal is a unique structure with two different kinds of joints on its borders. Since it is not surrounded by only osseous structures, intervertebral foramen gains a dynamic structure. As a consequence, during movements of the body its shape and diameter has changed. Under normal conditions these changes could be overcame by the neurovascular structures passing through the canal.

With a look from the spinal cord, i.e. medial viewpoint, intervertebral foramen is seen as circular, oval or upside-down teardrop shape. From the top to the bottom, postero-inferior edge of the body of upper vertebra, intervebral disc and postero-superior edge of the body of lower vertebra form the basement (anterior border) of the canal, respectively. In addition, lateral extension of posterior longitudinal ligament and anterior longitudinal venous sinus are also located on the anterior border. Free lateral edge of ligamentum flavum and the interarticular part of this bundle together with zygapophysial joint (facet joint) form the roof (posterior border) of the canal. Pedicles of upper and lower vertebrae form the superior and inferior borders, respectively. Spinal nerve canal is a canal beginning from the lateral side of the dural sac and continues with intervertebral foramen. The medial border of this canal is formed by dural sac and the lateral border is formed by fascial sheet on the medial of psoas. Branches of spinal nerve and segmental vascular structures pass through the passages within the bundles of this fascial sheet.

There is a pad formed of epidural fatty tissue around the nerve roots in intervertebral foramen. Lumbar nerve roots course close to the groove on the medial side of pedicle, just before entering the intervertebral foramen. This groove more significantly exists on the fifth lumbar vertebra and spinal canal enlarges laterally to this hole. These enlargements, which make the spinal cord seems like a three-leaved clover, are called as “lateral recess”. The narrowness in this area was described as lateral recess stenosis and it was stated that there could be a radicular type pain in the legs of the patients. Spinal nerve leaves the dural sac with a more oblique angle at the lumbar region with respect to the other regions. Because of this oblique pattern, spinal nerve extends from infero-medial side of upper pedicle through supero-lateral side of lower pedicle. The inappropriate infero-medial deviations during transpedicular approaches may cause complications for both spinal nerve and spinal cord.

## Ayhan Comert, MD

Department of Anatomy, Ankara University, Ankara, TURKEY

Ayhan Comert was born in January 4, 1975. He received a degree in medicine from Ankara University Faculty of Medicine in 2001 and then he completed the anatomy residency program of Ankara University Faculty of Medicine, Department of Anatomy in 2007. His currently works in Ankara University, Department of Anatomy. He published over fifty international original papers and he is a member of the Turkish Society of Anatomy and Clinical Anatomy and European Association of Clinical Anatomy. He serves on the editorial boards in three international journals and is a referee for various international journals. His scientific fields of interest are surgical neuroanatomy, bone-implant biomechanics and clinical anatomy.

# Vascular anatomy and its relationship to the lumbar intervertervertebral discs

*Ayhan C□mert, MD*

*Department of Anatomy, Ankara University, Faculty of Medicine, Ankara, Turkey*

Discectomy for decompression of lumbar disc herniation is one of the most common techniques. Perforation of the anterior anulus fibrosus and anterior longitudinal ligament with major vascular injuries is rare. However, serious complications may occur due to the proximity of the intervertebral disc to adjacent neurovascular structures. Life threatening vascular injuries, such as injuries to the aorta, inferior vena cava, common iliac arteries and veins has been reported. The major vessels, including the abdominal aorta, the inferior vena cava, the common iliac arteries and veins were situated directly anterior to the lumbar spine. These vessels, especially veins, are prone to injury during lumbar discectomy and a lesion of major arteries will cause profuse bleeding, which may progress rapidly fatal. Possible perforations which can occur during lumbar discectomies at different levels and angles and in different approaches to the spine were defined. The vascular anatomy of the anterior aspect of the lumbar vertebral bodies was variable from one cadaver to another. In general, the aorta was located in the midline and the inferior vena cava was situated to the right of the aorta. The aortic bifurcation was usually positioned immediately anterior to the body of the L4 vertebra and less frequently at L3-4 and L4-5 disc spaces. Commonly at L5-S1 level, the right common iliac vein crossed L5-S1 disc on right of the midline and the right common iliac artery overlaps the right common iliac vein. The left common iliac vein usually coursed lateral to the L5-S1 level but rarely coursed directly over the disc space. The left common iliac vein and artery run adjacent to them with no overlap on the left of midline. The inferior vena cava and the common iliac veins have a larger diameter and lie closer to the discs than the arteries and form a broad vascular band, especially at the L4-5 disc level. Because veins have considerably thinner walls than arteries, particularly the left common iliac vein which is adherent to the L5-S1 disc, it seems that veins were accidentally hit and punctured more often than arteries in anterior perforations. The median sacral artery crossed the anterior aspect of the L5-S1 disc near the midline traveling with the median sacral vein. Considerable variations have been found in previous anatomic and radiological studies of the abdominal aorta, inferior vena cava and their branches. Injury to the great vessels anterior to the intervertebral disc should always be kept in mind during disc surgery and the imaging techniques are useful in understanding the true relationships of the vascular anatomy with the intervertebral disc space. Injury to adjacent vascular structures during approaches to lumbar intervertebral discs is important and detailed anatomic knowledge of relationships is beneficial to decrease surgical complications.

## PERSONAL INFORMATION

| | |
|---|---|
| **NAME** | PIL SUN CHOI |
| **BIRTH DATE.** | 1958 – May - 16th. |
| **BIRTH PLACE** | Seoul – South Korea |
| **CIVIL STATUS** | Married (5 children) |
| **PROFISSION** | Doctor |
| **SPECIALTY** | Orthopedic and Spine Surgery |

## UNIVERSITY FORMATION

Graduated in 1982 in University of São Paulo (Brazil)

## MEDICAL RESIDENCE

Residence in Orthopedic and Traumatology in Orthopedic and Traumatology Institute of Hospital das Clínicas of São Paulo Medicine College of University of São Paulo. Period: 1984/1987. PS: Awarded as best resident in R1,R2 e R3.

## FORMATION IN SPINE SURGERY

Residence in Orthopedic and Traumatoloy in Orthopedic and Traumatology Institute of Hospital das Clínicas of São Paulo Medicine College of University of São Paulo. Period: 1984/1987

Fellowship in Lumbar Spine and Scoliosis Group in Orthopedic and Traumatology Institute of Hospital das Clínicas of São Paulo Medicine College of University of São Paulo.Period: 1996/2000

# Fundamental Anatomic Aspect To Safely Perform Pedicle Based Lumbar Spine Stabilization

*Choi, Pil Sun*

*Master of medicine (University of S o Paulo -B razil) and Chief of Minimally Invasive Spine Surgery Group of Abreu Sodr□Hospital (AACD)*

**Submitted for presentation: (x) computer**

**Study Design:** The lumbar pedicle morphometry and its relationship to the adjacent neural structures from L2-S1 were investigated by anatomic dissection in 14 human male adult fresh cadavers.

**Objectives:** The goal was to better understand the relationship between the lumbar pedicle and the adjacent neural structures.

**Summary of Background data:** The lumbar spine stabilization based on vertebral pedícle has been increasing to stabilize the motion segment for the treatment of several diseases. Recently with the advent of percutaneous implantation of the pedicles screws there were increasing necessity to better understand the exact anatomy of the vertebral pedicle and his relationship with the adjacent neural structures. Based on the study accomplished by Ebraheim in 1997, we decided to do anatomical study in cadavers to better understand the anatomy of that area.

**Methods:** The size of the lumbar pedicles was assessed by measuring its sagittal and transversal diameter. The relationship of the lumbar pedicle to the neural structures was evaluated by measuring the distance between dura-mater and the pedicle medial area, the distance between the most distal area of the pedicle and the nerve root that appears under it, and, the distance between pedicle apex and the nerve root that appears over it.

**Results:** The acquired results showed that the distance between the most distal area of the pedicle and the nerve root that appears under it, and the distance between the pedicle medial area and dura-mater, do not increase from L2 to L5, and they are in average 1,98 mm and 3,02 mm respectively. The distance between the pedicle apex and the nerve root that appears over it, increases from L2 to L5, varying from 13,64 mm to 21,62 mm in L5. The location of the spinal ganglion in relation to the pedicle has also been found, and 87% of the spinal ganglions are located in the foraminal zone.

**Conclusion:** The size of lumbar vertebral pedicle increases from L2 to L5 in both longitudinal and transversal diameter. The traversal diameter of the pedicle is smaller than the longitudinal. The lumbar vertebral pedicle has close relationship with the root that emerges below it and the most distal portion of the pedicle is adjacent to the root and its medial border is adjacent to the dura-mater.

**Ibrahim Ozkan AKINCI M.D.**

Department of Anesthesiology and Intensive Care Medicine

Istanbul Medical Faculty

University of Istanbul

Capa Klinikleri

34390 Capa, Istanbul, Turkey

Phone: +90 212 6318767

Fax: +90 212 5332083

e-mail: iozkana@yahoo.com

**Biographic Data:**

Date of birth: February 23, 1968

Place of birth: Ankara / TURKEY

Home address: ATA II Sitesi Sogut cd. Acelya sk. B7 4B No:2 D:4 Cengelkoy/Istanbul TURKEY

**Education:**

University: Istanbul Medical Faculty, University of Istanbul (1985-1991)

**Occupational History:**

November 1991- December1992: I worked as a general practitioner in Ezine/ Canakkale for governmental service

January 1993- April 1997: I completed my residency program in Anesthesiology and Intensive Care Department of Istanbul Medical Faculty

May 1997- January 1999: I worked as a consultant in the Intensive Care Unit of Istanbul Medical Faculty

February 1999-April 2000: I performed my military service in Siirt Military Hospital

May 2000 to February 2002: I continued to work as a consultant in Intensive Care Unit of Istanbul Medical Faculty

February 2002 to March 2004: I worked at Northwestern University, Division of Pulmonary and Critical Care as a postdoctoral research fellow.

June 2004 to present, working at Neurosurgery Department of Istanbul Medical Faculty as faculty of Neuro-Anesthesia and Critical Care.

October 2006 got the degree Associate Professor of Anesthesia.

**Research Interests:**

Mechanical ventilation, ventilator induced lung injury, oxygen induced apoptosis, signal transduction, aneurismal subarachnoid hemorrhages, neuromuscular blockers in neuro-anesthesia.

# Awake and General Anesthesia in MISS

*I. Ozkan Akinci*

*Anesthesiology Dept., Istanbul University, Istanbul Medical Faculty*

Minimal invasive surgical procedures on spine (MISS) are getting more popular due to the advantages of short term hospital stay, recovery period and cost effectiveness. After the surgical procedure, patient goes back to normal life and work early which is another major advantage of MISS. As we all know, MISS could be performed at all levels of spine percutaneously and/or sometimes via penetrating of thorax or abdominal cavity. Due to the procedure site, general or local anesthesia with conscious sedo-analgesia is the choice of anesthetist and surgeon. Sedo-analgesia is the choice for percutaneous procedures for lumber or thoracic lesions, but abdominal and thoracal penetrating procedures and percutaneous cervical procedures are mostly done under general anesthesia.

During disc decompression, while reducing intradiscal pressure and tension on outer line of annulus fibrosus, adjacent nerve root should be protected, for this purpose pain relief and reflecting pain on leg or arm are important sings to perform correct treatment. But while surgeon is following the changes of his patient's pain during procedure, this pain shold be minimized to a level that wouldn't disturb patient. Also the level of pain relief should not mask any complication during surgical procedure. In addition to pain relief induction of amnesia for relieving discomfort of pain and surgical procedure could help. Because of that, sedo-analgesia and local anesthetic combination gives surgeon a good guidance to catch all sings of pain during procedure, and patient can also easily and comfortably tolerate the procedure. For sedo-analgesia, anesthetist should pick the short half-life drugs for sedation and analgesia. During procedure a short half-life opioid (Remifentanyl: 0.025-0.2 $\mu$gr/kg/min.) and benzodiazepine (midazolam: 0.01-0.02 mg/kg initial dose, subsequent doses should be titrated slowly and administered at least 2 minutes later) could be used for analgesia, sedation, anxiolysis and amnesia. Apnea, muscle rigidity and tachycardia are most frequent side effects of remifentanil. Additional midazolam, while increasing the apnea incidence of remifentanyl, decreases the muscle rigidity and tachycardia incidence.

As an alternative sedo-analgesic approach, dexmetodomidine infusion (0.2-0.7 mg/kg/h infusion after 1 mg/kg/10min loading dose) could be used, which is an alpha agonist agent. Because of its sedative and mild analgesic effect, it can also be used with an opioid agent like fentanyl or alfentanyl (1-2$\mu$gr/kg or 0.1-0.2). While lack of amnesia affect of dexmetodomidine is a negative effect, less apnea incidence during infusion is a positive effect of this agent.

As we mentioned before, cavity penetrating MISS and cervical procedures are performed mostly under general anesthesia, because even little movements could cause a nonreturnable damages on spinal cord or nerve roots during cervical procedures. Again short half-life anesthetic drugs should be chosen for anesthetic care. Propofol 2-2.5 mg/kg and fentanyl 1-2 $\mu$gr/kg atracurium or cis-atracurium combination could be used for hypnose, analgesia and muscle relaxation.

All patients should be monitored for ECG, SpO2, arterial blood pressure and respiratory rate and continuous follow up by an anesthetist is also crucial.

As a result, local anesthesia with conscious sedo-analgesia is the best option for lumbar MISS but general anesthesia is safer for cervical and cavity penetrating procedures.

## Prof. Fusun GULER-UYSAL, MD

Dr.Fusun Guler-Uysal graduated from Hacettepe University School of Medicine, Ankara, Turkey in 1987. She studied Physical Medicine and Rehabilitation between 1989-1993 as a resident at Hacettepe University, School of Medicine, Department of Physical Medicine and Rehabilitation. After earning her degree as a Physical Medicine and Rehabilitation specialist, she worked at Ankara Rehabilitation Center through 1993-1996. Dr.Guler-Uysal worked as a research fellow at Erasmus University School of Medicine, Department of Rehabilitation in 1996-1997 where she took part in clinical studies on pregnancy-related pelvic pain. She started as assistant professor at Cukurova University, School of Medicine, Department of Physical Medicine and Rehabilitation in 1997 and received her associate professorship in 1998. Dr.Guler-Uysal was certified by the European Board of Physical and Rehabilitation Medicine in 2002 and was assigned as a clinical professor in 2005. Through 2003-2007, she was interested in improving medical education in Turkey and took responsibilities in areas like forming the new medical curriculum and improving training abilities of the faculty at Cukurova University, School of Medicine. She has also been involved in resarch activities and is the author of numerous research articles on back and pelvic pain, osteoporosis and other metabolic bone diseases, effects of exercise and physical therapeutic modalities in rheumatic deiseases. Dr. Guler-Uysal is performing her practice in her private clinic in Istanbul since 2007 where she is mainly dealing with painful syndromes of the spine and osteoporosis along with rehabilitation of sports injuries and rheumatic diseases.

# Outcome Measures In Low Back Pain

*Prof. Fusun Guler-Uysal, Md*

Outcome measures are tools for measuring the outcome of health care interventions over time. They have been used in clinical practice and research settings to evaluate the effectiveness of treatment techniques. In low back pain (LBP), pain has been described as one of the cardinal domains to be assessed along with back-specific function, generic health status, disability and quality of life as evaluated with patient self-report measures. Measurement of pain often yields much greater treatment effect sizes, or responsiveness, than physical variables or condition-specific instruments (i.e. it is the more 'sensitive' measure for evaluating the effects of treatment). Finally, and of importance, the patient typically seeks care due to pain, and hence this is the variable that needs to be carefully assessed both at baseline and in response to treatment. When dealing with acute LBP, location and intensity of pain at rest often suffices in clinical practice. However, assessment of acute pain during movement (dynamic pain) is more important than pain at rest. Research has shown that numeric scales such as visual analogue scale and numeric rating scale are superior to verbal scales in acute pain. Chronic LBP, on the other hand, is much more complicated to evaluate since it is a complex experience of multipl dimensions. Pain affect (bothersomeness), quality, frequency and impact of pain on daily activities should be assessed along with intensity and location. Categorical scales with verbal descriptors or numerical rating scales seem to be preferable to traditional visual analogue scales in chronic LBP. Other aspects such as pain coping strategies, pain tolerance and pain-related anxiety might also be important to evaluate. Additional tools covering dimensions like functional status, quality of life, work or social disability along with spesific diagnostic studies should complement the assessment of chronic LBP paitents. Development of a core set of outcome domains and measurement procedures would facilitate comparison and pooling of data. The Initiative on Methods, Measurement and Pain Assessment in Clinical Trials (IMMPACT) group has proposed a core set of outcome measures for pain trials. As for disability due to LBP, many questionnaires have been used both in research and clinical settings, and recently, core sets of items have been proposed based upon the International Classification of Functioning, Disability and Health (ICF). In clinical practice, the use of these measures may present a considerable burden to patients as well as to hard pressed health care professionals. Computerized Adaptive Testing (CAT) approach for measuring disability in LBP uses a previously calibrated set of items called an item bank and selects the most informative items for each individual patient according to their level on the construct being measured. The CAT approach allows for the collection of precise outcome information that can simply be applied in both clinical and research settings. There are still problems in what constitutes a ''successful'' outcome and how best to measure it in managing LBP. A statistically significant improvement may reflect a benefit that is clinically meaningless. Clinicians should be aware of the psychometric properties of the tool to be used and determinations of statistical significance must be supplemented by consideration of the clinical importance of changes in outcome measures.

## Elvan Erhan, MD, FIPP

Place of Birth: Manisa, Turkey, Date of Birth: June 8, 1967

Adres: Department of Algology, Ege University, Faculty of Medicine, 35100, Izmir, Turkey

E-mail: elvanerhan@yahoo.com, elvan.erhan@ege.edu.tr

Education: 1973-1978: Gazi Elementary School, Manisa

1978-1982: American Collegiate Institute, Izmir

1982-1985: Science High School, Ankara

1985-1991: Ege University, Faculty of Medicine, Izmir

**Work Experience:**

1992-1996: Ege University, Faculty of Medicine, Department of Anesthesiology and Reanimation (resident)

1996-2000: Ege University, Faculty of Medicine, Department of Anesthesiology and Reanimation, Department of Algology (specialist)

2000-2003: Ege University, Faculty of Medicine, Department of Anesthesiology and Reanimation, Department of Algology (Assistant Professor)

2003-2009: Ege University, Faculty of Medicine, Department of Anesthesiology and Reanimation, Department of Algology (Associate Professor)

2009 - : Ege University, Faculty of Medicine, Department of Anesthesiology and Reanimation, Department of Algology (Professor)

29/9/2007: World Institude of Pain (WIP) – Pain Practice Board Examination, Fellow of Interventional Pain Practice (FIPP)

2007: Turkish Society of Algology, Board Certificate

Membership of Associations: IASP (International Association for the Study of Pain), WIP (World Institute of Pain), Turkish Society of Anesthesiology, Turkish Society of Algology, Turkish Society of Regional Anesthesiology

She is the author of 18 international and 30 national scientific papers, author of 1 international book chapter and 12 national book chapters. She has presented and given talks in international (63) and national (55) scientific meetings. She is also reviewer or editorial board member of international (5) and national (3) scientific journals. She speaks English. She is married and has one daughter.

# Interventional Techniques For Low- Back Pain

*Elvan Erhan, MD, FIPP*

*Professor, Department of Algology*

*Ege University, Faculty of Medicine, Izmir, Turkey*

The annual prevalence of chronic low back pain ranges from 15% to 45%, with a point prevalence of 30%. Low-back pain is associated with significant economic, social, and health impact. The number of patients receiving spinal interventional techniques such as needle placement of drugs in targeted areas, ablation of targeted nerves, and implantation of spinal cord stimulators increase every year. This increase in utilization parallels the rising prevalence of low back pain, advancement of new and innovative fluoroscopic injection techniques and the evolution of new interventional pain management modalities.

Lumbar intervertebral discs, facet joints, sacroiliac joint, ligaments, fascia, muscles, and nerve root dura have been shown to be capable of transmitting pain in the lumbar spine with resulting symptoms of low back pain and lower extremity pain. Diagnostic and therapeutic spinal interventional techniques in the management of low-back pain include facet joint interventions, sacroiliac joint interventions, epidural injections, lumbar epidural adhesiolysis, discography and intradiscal therapies, mechanical disc decompression, and implantable therapies.

The diagnostic blocks applied in the precision diagnosis of chronic low back pain include lumbar facet joint nerve blocks, lumbar provocation discography, and sacroiliac joint blocks. Faset joint pain prevalence is 21% to 40% in heterogenous population with chronic low back pain and 16% in post lumbar surgery syndrome. Diagnostic lumbar facet joint nerve blocks are recommended in patients with suspected facet joint pain. Primary discogenic pain is reported in 26% of patients suffering with chronic low back pain. Discography is a procedure that is used to characterize the pathoanatomy/architecture of the intervertebral disc and to determine if the intervertebral disc is a source of chronic low back pain. Lumbar discography may help to identify symptomatic and pathological intervertebral discs. The prevalence of sacroiliac joint pain is estimated to range between 10% and 38%. Due to the inability to make the diagnosis of sacroiliac joint-mediated pain with non-invasive tests, sacroiliac joint blocks appear to be the evaluation of choice to provide appropriate diagnosis. Controlled sacroiliac joint blocks with placebo or controlled comparative local anesthetic blocks are recommended when indications are satisfied.

After diagnostic local anesthetic blocks, facet joint pain may be managed by intraarticular injections, medial branch blocks, or neurolysis of medial branches. Percutaneous neurotomy of medial branches may be performed by radiofrequency (RF) thermoneurolysis utilizing conventional RF (heat destroys nerves and blocks pain transmission) or pulsed RF (heat never exceeds 42o C preventing damage to the tissues and the nerves). After diagnostic blocks, sacroiliac joint pain may be managed with intraarticular injections and L5-S3 medial branch RF (Conventional RF, Pulsed RF and Cooled RF). Multiple intradiscal therapies described to manage either discogenic pain or IDD include Intradiscal RF Thermocoagulation (IRFT), Intradiscal electrothermal therapy (IDET), Intradiscal Thermal Annuloplasty (IDTA), Intradiscal Biaculoplasty (IDB), Intradiscal dual RF (IDRF), Intradiscal Pulsed RF (IPRF). RF of the communicant ramus and sympathetic ganglions may be performed for discogenic segmental pain. Caudal, epidural transforaminal steroid injections, epidural neuroplasty, dorsal root ganglion (DRG) pulsed RF may be performed for radicular pain and failed back surgery syndrome (FBSS).

Interventional pain management is a rapidly growing field. The importance of spinal interventional techniques in managing chronic spinal pain has been established on the basis of advances in imaging, neuroanatomic findings, and the development of precision diagnostic and therapeutic injection techniques. Numerous new procedures or modifications of old procedures are being introduced nearly every year in the last two decades. There is increasing evidence supporting the use of spinal interventional techniques in managing spinal pain.

# Ismiss And Endoscopic Spinal Surgery: Facts And Update 1989-2010

*Leu Hj., PD Dr.med.; President ISMISS 2008/2011 www.ismiss.com*

*Bethania Spine Base, Orthopaedic spinal surgery*

*CH-8044 Zurich / Switzerland – bethania-spine@bluewin.ch*

It was around 6 years after introduction of endoscopic spinal surgery when in 1988 three of the pioneers in the field, S.Hijikata (Jp), P.Kambin (USA) and A.Schreiber (CH) became aware of the potential of minimal invasive technologies that was to communicate and further develop in common; so ISMISS was founded in 1989 as a non profit organization. Its focus remain the further technical development and clinical education in minimal invasive operative techniques. Instructional symposia and workshops are organized on a regular base. Recently ISMISS has published first time worldwide respective guidelines for endoscopic spinal surgery ( http://www.ismiss.com/5-0-Guidelines.html ). First time intradiscal endoscopy was performed 28th years ago at Balgrist University of Zurich. There already in 1979, based on Japanese uniportal percutaneous technique of closed percutaneous nucleotomy, this miminal invasive intradiscal decompression was introduced in Europe and soon improved in effectivity by a biportal posterolateral approach. Additional biportal endoscopy was engaged so in 1982 for visual monitoring of intervertebral tissue elaboration. Beside decompressive indications, in 1987/88, in combination with percutaneous external pedicular fixation, endoscopy controlled interbody fusion was introduced. After nearby a decade in clinical experience with biportal intradiscal decompression, the idea arised to combine simultaneous endoscopic control with direct extradiscal tissue elaboration across an uniportal approach in the later eighties. Experiments with modified urologic workings-scopes designed for cystoscopic applications demonstrated in 1990, that endoscopic applications are possible also in non-preformed anatomical spaces when some hyperpressive irrigation was used for local atraumatic tissue spacing. So we introduced endoscopic coaxial foraminoscopy clinically for the first time in February 1991 for the treatment of a foraminal sequestrated herniation. A first publication on the early series was published in 1996. Since then the technology with improved endoscopic tools and irrigation systems as well as high-frequency coagulation under irrigation became almost standardized for this specific range of indication. The posterolateral approach from 9-12 cm from the midline follows the same criteria as for intradiscal applications, but the working cannula is directed to the foraminal sequestrum, which is extracted under endoscopic control then with a special working scope. After a steep learning curve today the optimal indications and contraindications are clearely defined with all forms of extra-, intra- and medioforaminal type of herniations. Our clinical series of 220 standardized cases brought successful primary results in 176 cases, including the learning curve. Hereby in the foraminal applications, the results trend to “black or white”: or the sequester is removed or not. Relatively freshly sequestrated fragments without local scar-adhesions are easier to remove. Anatomical limits can occur in L5/S1 when high iliac crests can impair flat approach to medioforaminally located sequestra. For preop evaluation a 3d-CT offering clear bony analysis of accessible trajectories or explorative discography can trace the access precisely. Detailed knowledge of foraminal anatomy is mandatory. Hospital stay could be reduced to 2 to 3 days, out-patient care is possible nowadays as well. In 2002 pioneering contributors as Ruetten in Germany brougt up the interlaminar endoscopic lumbar decompression, what definitely extended the range of application of the minimal endoscopic approach also to more mediolateral forms of lumbar disc herniation. In recent years with improved bone decompression instruments, the endoscopic way was extended also to dorsal cervical extradiscal application. So the available complementary endoscopic techniques, in well trained hands, today challenge definitely the conventional golden standards such as as microdiscectomy.

**Reference :** Leu Hj., Hauser R.: Die perkutan posterolaterale
**Foraminoskopie :** Prinzip, Technik und Erfahrungen seit 1991. Arthroskopie 9(1996)26-31u

# Anatomical Rationales For Minimally Invasive Spine Surgery

*Wolfgang Rauschning, MD, PhD,*

*Department of Orthopaedic Surgery, Academic University Hospital, S-751 85 UPPSALA, Sweden*

The cascade of lumbar motion segment degeneration includes internal disc disruption, disc dysfunction due to the delamination of the annulus fibrosus, and also slackening and incompetence of the outermost annulus, longitudinal ligaments, inter-and supraspinous ligaments and instability/subluxation of the facet joints, all reflecting the dysfunction of the spinal segment. In the early stages of DDD these stabilizing structures are anatomically intact, although relaxed and therefore not functioning properly due to altered mechanics and insertion sites.

Intradiscal therapy and genetic engineering with the aim of decelerating, halting or even reversing this degenerative cascade, such as disc cell culture injections, may in a distant future become an alternative to fusion surgery and currently available motion-preserving surgical techniques. The biological acceleration of fusions would appear to be an alternative option. The problem with such biological options, however, is the deleterious impairment of segmental spinal mechanics that inevitably exert enormous forces on the stabilizing anatomical elements.

In degenerative disc disease the impairment of nutrition pathways into the disc and the inability of the disc to dissipate toxic metabolic products, create an extremely hostile intradiscal environment with low pH, the formation of protease, cytokinines, prostaglandines, hypoxidity, dehydration, loss of proteoglycans and thereby turgor (swelling pressure). This toxicity leads to irritation of the fine nociceptive nerve endings which over the age of 50 penetrate the miniscule crevices of the endplate which thereby becomes painful. The toxic environment also causes necroptosis of the disc cells. Disc cell cultures injected into degenerated discs have a rather limited number of life cycles. It therefore has been stated that biochemical and biological treatment should be complemented with mechanical measures that restore some of the normal kinematics and biomechanics of the motion segment.

In early stages of the cascade, the internal disruption of the disc and early endplate changes reflect the disturbance of fluid transport through the endplate, and also a disequilibrium between the intradiscal and the intravertebral=intraosseous pressure. In later stages the cross-linkages between the annular collagen lamellae are progressively broken by a combination of malnutrition and mechanical attrition. Later stages of the disease encompass gross delamination of annular lamellae, sometimes with vacuole formation and the separation of the inflamed outermost annulus fibrosus from the remainder of the disc.

When tears of fissures sever the outermost annulus fibrosus, blood vessels are sprouting into the disc, frequently accompanied by nociceptive pain fibers (neovascularization). Larger and long-standing annular tears are typically sealed by a callus-type cellular granulation tissue which is richly vascularized and innervated. This granulation tissue is the pathoanatomical substrate of the High Intensity Zone (HIZ) that is frequently observed in the posterior central portion of degenerated discs on MR scans of patients complaining of non-dermatomal (mechanical) low back pain, “discogenic pain”, but also in subjects without any such symptoms at all. Endoscopic and other minimally invasive treatment options for the various stages of DDD are discussed along with the pathoanatomical changes.

In the lumbar and lumbosacral spine the cascade of degenerative disc disease (DDD) is demonstrated in view of the currently available surgical treatment options. The pathoanatomy of “low-back-pain” and “radiculopathy” is mirrored against current treatment options, ranging from chemonucleolysis, percutaneous disc ablation, a variety of laser disc ablation options, coblation, and IDET, to hydrogel nucleus prosthesis, PDN, a wide array of fusion techniques such as cages for PLIF and ALIF applications, femoral ring and precision crafted allograft fusions and artificial disc prostheses. As an intriguing alternative, the concept of neutral dynamic distractive stabilisation of the lumbar spine in painful mechanical dysstabilities and spinal stenosis in younger patients is briefly outlined.

We also conducted a cadaveric-experimental study pertaining to posterior percutaneous or endoscopic surgical approaches to the intervertebral discs. The study clearly showed that any uni or biportal approach to the lower lumbar spinal discs carries potential risk for injury or violating blood vessels or neural structures, in particular the delicate dorsal root ganglia.

In all postsurgical specimens of patients who had had posterior lumbar surgery, extensive scar transformation of the erector spinae muscles was consistently observed. Not only were the erector trunci muscles affected, but also the deep short oligosegmental muscles which account for the proprioception and fine-tuning of segmental mobility. In short as well as in long instrumentation, the scarring extended one or two levels above and below the intended instrumentation. All back muscles are contained in a non-expansile osseoaponeurotic compartment. When contracted, they constitute a powerful “dorsal soft tissue column” which stabilises the lumbar spine. Surgery must minimise violation of these muscles to avoid failed back surgery sequelae. In view of these findings, not only “muscle-sparing” but allout “tissue-sparing” approaches AND procedures are called for. Until proven otherwise, every structure comprising the vertebral column as well as the spine, must be considered indispensable and worthy to be respected and preserved, provided that less “invasive” techniques provide acceptable access and visibility without unduly impeding and prolonging the surgical procedure at hand. In some instances a tissue-sparing “open” approach may well lend itself as an alternative to scopes and lasers…

**Robert N. Hensinger, M.D.**
**William S. Smith Professor**
of Orthopaedic Surgery
1500 E. Medical Center Drive
2912 Taubman Center, Box 5328
Ann Arbor, MI 48109-5328
(734) 936-5715
rnh@med.umich.edu

## Education and Training

08/1952-06/1956 High School, St. Mary High School, Jackson, Michigan
09/1956 – 06/1960 Undergraduate, A.B., University of Michigan
09/1960 – 06/1964 Graduate, M.D., University of Michigan

# Minimally Invasive Surgery On The Pediatric Spine

*Robert N. Hensinger, MD*

*University of Michigan, Ann Arbor*

Techniques for minimally invasive spine surgery (MISS) have only been widely used in the past decade. Currently, the most commonly used MISS procedure in children is video assisted thoracic surgery (VATS). We have had extensive experience using VATS for anterior release and fusion for scoliosis and kyphosis. Scheuermann's kyphosis continues to be an indication for anterior release and bone grafting, which achieves a much better correction of the kyphosis and, indirectly, the compensatory lumbar lordosis. VATS with instrumentation can be used for correction of thoracic curves in patients with idiopathic scoliosis. In addition, VATS has been useful in conjunction with posterior spine fusion for severe scoliosis (>90 degrees). However, with more extensive use of pedicle screw fixation to achieve curve correction, many surgeons have returned to a posterior approach alone for scoliosis correction. Indeed, correction of thoracic scoliosis with anterior instrumentation has limited indications, including moderate curve size and flexibility. Positioning of the instrumentation is critical as the screws can be close to vital structures, particularly the aorta. Further, the anterior placement of dual rods to increase construct stiffness during fusion is technically challenging. These drawbacks have dampened initial enthusiasm for the procedure.

VATS has also been used to insert various implants for guided growth of the spine. By slowing unilateral growth, these implants can gradually correct curvature of the spine in the growing child. Several spine centers have been working on a number of promising techniques to gradually correct scoliosis in children. VATS can be helpful for the treatment of congenital scoliosis, both for hemiepiphyseodesis and removal of hemivertebra with a combined anterior/posterior approach.

There has been limited application of MISS in children with spine tumors, such as removal of osteoid osteoma. However, MISS has been particularly helpful for tumor biopsies.

In the treatment of osteomyelitis, MISS has been used for biopsy and drainage of abscesses, especially for tuberculosis. It has not been widely used for anterior stabilization of spine fractures in children. However, it does have application for short segment posterior fusion of 1-4 levels, such as in the direct repair of a spondylolysis or fracture stabilization.

There are limitations to the use of MISS in children, primarily because of complications associated with anesthesia and ventilation of one lung. Prone positioning can help minimize the need for single lung ventilation, and allows for proceeding to posterior spine fusion when necessary. Previously, small children under 20 kg were considered poor candidates for VATS, but recent advances have allowed limited use in this population. This technique is still in its infancy and there is still a steep learning curve; many of the applications are experimental. Indications for use of MISS for deformity correction are being explored. In the future, as better equipment becomes available, particularly for guided growth and gradual correction of scoliosis in the young child, MISS is likely to gain popularity.

RNHMINIMALLYINVASIVE

# Novel Treatments of Degenerative Lumbar Disc Disease

*Howard S. An, M.D.*

*Professor of Orthopaedic Surgery, Director of Spine Surgery,*

*Rush Medical College at Rush University Medical Center, Chicago, IL*

Pathogenesis of Lumbar Disc Disease: Although the exact pathogenesis is unknown, the patho-etiologies of degenerative disc disease involve genetic, biomechanical, and biological factors. The intervertebral disc consists of outer annulus fibrosus (AF), which is rich in collagens that accounts for its tensile strength, and inner nucleus pulposus (NP), which contains large proteoglycans and water for resisting compression loading. The chondrocyte-like cells in inner AF and NP produce matrices under the control of a variety of substances including growth factors and bone morphogenetic proteins (BMPs). Catabolic process or breakdown of the matrix is mediated by various matrix metalloproteinases (MMPs) and cytokines. There is balance between the anabolic and catabolic processes in the normal disc, but this balance is lost in degenerating discs. The intervertebral disc also requires nutrition, mainly by diffusion from the vertebral bodies and endplates. Therefore, trauma, cigarette smoking, and other factors that affect the endplates may affect diffusion and affect nutrition to the disc cells. The aging and degenerative changes in the intervertebral disc affects the facets joints and the kinematics of the motion segment changes that could be detected with novel imaging studies and motion preservation devices could be used to restrict or maintain motion in certain directions. It should be emphasized that pain is not necessarily correlated with morphologic or biomechanical changes in the motion segment, and further studies are needed to elucidate the mechanism of pain in degenerative disc disease. Emerging Novel treatments of Lumbar Disc Degeneration: Current treatments of low-back-pain due to disc/facet degeneration include fusion, artificial disc, and perhaps intradiscal electrothermal therapy (IDET) in patients who have failed months of conservative treatment. Emerging novel treatments include posterior motion preservation procedures, artificial nucleus pulposus, and biological intradiscal injections that are not FDA approved but undergoing clinical trials. Artificial nucleus pulposus may have indications in which the annulus and posterior facets are intact in the relatively early stage of disc degeneration. Even though many posterior motion preservation devices are being developed at present, lack of knowledge in the relationship among kinematics, spondylosis and pain is a significant hurdle in treating mechanical LBP with these types of devices. Biological repair or regeneration is feasible by injecting a growth factor or BMP such as OP-1 or GDF-5 or blocking cytokines such as TNF-a or IL-1 that are involved in matrix degradation. Alternatively, transplanting stem cells, chondrocytic cells or cells that are transfected with therapeutic DNAs by viral or non-viral gene therapy have shown some promise. These therapies could restore the degenerated disc but effect on pain relief is not known. Further research on pathogenesis of IVD degeneration and pain mechanism should also be considered.

# Endoscopic Spine Surgery

*Fujio Ito*

*Aichi Spine Institute*

[Introduction] Percutaneous Endoscopic Lumbar Discectomy (PELD) is a one-night stay surgery with a 7mm incision under local anesthesia. Micro –Endoscopic Discectomy (MED) is two-stay surgery with a 16mm incision under general anesthesia. We will discuss the comparison, indication and outcomes between PELD and MED. [Objectives] Objects are to determine the indication and avoid repeating the unsuccessful cases. [Methodology] 669 cases of herniations (623 patients) were treated by PELD that were Transforaminal approach (374 cases), Interlaminar (199 for L5/S1), Extraforaminal approach (84 for lateral herniation) and 12cases of double lesions. 167 cases of herniation (158patients) were treated by MED. The indication of PELD was the herniation with migration less than 1 cm, central huge herniation, lateral herniation, and except combined with lateral recess less than 3mm at the portion of the pedicle. The indication of MED was the herniation with migration more than 1 cm, the herniation with lateral recess less than 3mm and osseous hypertrophy of spondylolysis, and the cases of narrow interlaminar space of L5/S1. The following are the results of the Visual Analogue Scale and Japanese Orthopedic Association scores. [Results] Average age was 48.4±17 years old in PELD and 54.1 ±15.6 in MED. Operation time was 58±19 minutes in PELD and 126±50 in MED. There was no significant difference between PELD and MED in terms of Sciatica, back pain and JOA score over a period of 6 month. Nearly 90% were satisfactory in the improvement rate of among the both. However, revisions of PELD were 75 cases 12% which were by 25 recurrences, 19 remnants, 11 cases of impossible due to insertion pain, 10 nerve adhesions, 2 instabilities and 2 lateral recesses which were mistaken preoperatively, and 6 others such as dura tear, mistook level, 2 bleedings or blood pressure decrease. 73% of PELD revisions were successful. 26 of them were MED under general anesthesia, 46 were PELD under local anesthesia, 2 were TLIF and one was open surgery. Finally, 94% of initial PELD operations were completed with excellent and good results. On the other hand, revisions of MED were 18cases 11%. All of MED revision cases were treated by the same method and were satisfactory in 62%. In the end, 90% of initial MED operations were completed with excellent and good results. [Conclusions] PELD is suitable for the majority of lumbar disc herniations. It's important to check pathological bone changes, the diameter of the interlaminar space and the foramen by 3D-CT before the operation. Be careful of damaging the ganglion. MED is suitable for the herniations with osseous problem and far-migration.

# Is there a place for minimal invasive and endoscopic surgery on the lumbar and cervical spine

*Stefan Hellinger,*

*ISAR Klinik Munich*

Endoscopy became very early part of the surgical techniques. In 1807 the first endoscopic procedure was described by Bozzini and 1879 the first working channel endoscope was described by Nitze. Reasons for this developments had been the requirements of the improvement of visualisation in the operation field even at this time. In the neurological surgery the use of endoscops started by L'Espinase in the Brain. As Pioneers acted surgeons like Dandy or Mixter (beside the disc surgery). Cause of technical limits these procedures went forgotten. The open surgery especially on the spine went forward and braught a lot of new techniques, which are now standard and part of residency trainings.

At the end of the 80ies the technology for endoscopes made a step forward what leaded to a recovery for the neuroendoscopy. On the spine surgeons like Kampin, who made the first working channel scope for disc herniations, gave a new input.

This step was made by the confrontation with disadvantages of open surgery and the goal to minimize the surgical morbidity by using the new techniques of visualisation and surgery.

The endoscopic surgery of the spine allows a minimal surgical trauma on the approach, to do surgery only in the region of pathology even under local anaesthesia, avoids postagressive metabolism and gives a fast recovery to the patient. At all it is a minimal aggressive surgery.

To do these techniques special skills, trainings and knowledge are required. Also the use of the new technical possibilities must be learned.

Meanwhile exist a lot of different endoscopic techniques on the lumbar and cervical spine.

Especially the differnet approaches, transforaminal, interlaminar, translaminar on the lumbar spine as well as the anterior or posterior on the cervical spine must be common for an endoscopic surgeon.

Nowadays all kinds of discal pathologies beside stenosis can be treated by endoscopy. Diseases like spinal cysts re also a good option for this technique.

The value of these techniques has been proofed in a lot of scientific papers till randomized controlled studies beside our dayly experience.

The endoscopic surgery of the spine today is a less traumatic and effective option for the surgery of the spine beside the classical microsurgery. There will be further developments of these techniques even to minimalize fusion and stabilisation technology. A proper training of the surgeons from today and tomorrow would be an essential part of an adaequate placement.

# Percutaneous Endoscopic Lumbar Discectomy By Contralateral Approach For Distally Migrated Hernia

*Jae- Yoon Chung, M.D. and Jae- Joon Lee, M.D.*

*Dept. of Orthopaedics, Chonnam National Univ. Hospital, Gwangju, 500, Korea*

Introduction : Percutaneous endoscopic lumbar discectomy (PELD) has been widely used procedure. Although various techniques and approaches to herniated disc have been tried to extend the indications of PELD, distal migration with abutment on the medial wall of pedicle is not easy to approach. The purpose of this study is to introduce contralateral approaching portals to be easy of access to distally migrated lumbar disc herniation and to evaluate the clinical results.

Material and method : From August 2004 to May 2008, we have experienced ten cases of lumbar disc herniation which were migrated distally, that were Story 3 by the three-storied anatomical house concept and abutted on the medial wall of pedicle. Herniation of disc was occurred at L2-3 in two, at L3-4 in two, and at L4-5 in 6. Eight cases were approached by contralateral transforminal route and two cases by contralateral interlaminar route using 2.5mm working channel endoscope. Performing contralateral transforaminal approaches, 5mm-diametered trephine was used to enlarge the neural foramen in 3 cases. Preoperatively, localization of herniated disc was done by preoperative MRI and accessibility was evaluated by CT and MRI, and postoperatively CT or MRI was taken. Clinical outcomes were evaluated by the improvement of preoperative pain.

Result : In all cases, preoperative radiating pain was improved. Low back pain score was improved form 45 points preoperatively to 82 points postoperatively. Numeric rating pain scale was 2.2 against 10 preoperative reference values. There was one case of exit root symptom of approaching side neural foramen in transforaminal route. In the case of contralateral interlaminar approach, mild hypesthesia was developed on the corresponding nerve root dermatome. Simple dural tear was occurred in one case.

Conclusions: Percutaneous endoscopic discectomy for distally migrated herniation with abutment on the medial wall of pedicle was successful via contralateral transforaminal or interlaminar approach without significant complications. We suggest these approaches can be one of the advanced techniques to extend the indications of PELD, and can be applied especially at the level of higher than L5-S1.

## Hikmet Ulug

Sex: Male
Date of Birth: 15.08.1957
Place of Birth: Turkey
Marital Status: Married
Nationality: Turkey
Present Address: MedicalPark Fatih Hospital Istanbul/TURKEY
Phone: 00 90 532 6167313

FAX:
E-mail: hikmet.ulug@gmail.com
Personal Profile
Chief of Neurosurgery Department

**Education and Qualifications**

Date
18-19 September 2009 14 th International Training Course for Full-endoscopic Operations of the Lumbar Spine Herne/Cologne Germany

**Date**
24-29 August 2009 57 th International MISS Course Seoul/S.Korea

**Date**
2004 CyberKnife training Accuray/San Fransisco/USA

**Date**
1992 Microsurgery training Zurich University Neurosurgery Department

**Date**
1988-1991 Chief Resident and Instructor University of Ankara Medical Faculty Neurosurgery Clinic

**Date**
1983-1988 University of Ankara Medical Faculty Neurosurgery Resident

**Date**
1981 University of Ankara Medical Faculty

# Learning Curve In The Interlaminar And Transforaminal Full Endoscopic Lumbar Discectomy (Feld): Pitfalls And Crucial Points

*M. Hikmet Uluğ M.D.* *Soner Büyükkınacı M.D.*

*Bakırköy Neurology Center and MedicalPark Hospital*

Full endoscopic lumbar discectomy has become popular in the recent years and has similar success rates with the conventional microdiscectomy procedures. The decrease of surgical morbidity, the inexistance of the postoperative epidural scar tissue, the minimal tissue damage are the most adventageous features of FELD operations. Among the FELD procedures, the posterolateral/lateral transforaminal approach is the most widely accepted technique. On the other hand, the posterior interlaminar approach is being used as another method. Due to the application of these two techniques, the endoscopic procedures become to have a wide area of usage in the lumbar dics herniations. The most important disadvantage of the both techniques is their steep learning curve. The initiation of the application of these interventions and the making endoscopic surgery as a routine procedure is a challenging process particularly in a clinic in which the endoscopic surgery is not traditionally used. Although the transforaminal and interlaminar interventions are being performed with the similar equipments basically, they have different technical properties. But the common feature of the two methods is the completely different surgical tool usage in general. In this article, the challenges experienced during the initiation of these techniques and the stages of the application in a clinic in which the endoscopic surgery is not generally used have been assessed. Additionally the first six months results after surgery have been evaluated.

# Endoscopic Transforaminal Microdecompressive Lumbar Disc Surgery With GPS For Morbid Obese Patient

*John C. Chiu, M.D., Frcs, D.Sc*

*California Spine Institute*

**Purpose:** Morbid obesity is characterized by an individual weighing more than 100 pounds over his or her ideal body weight, or having a body mass index (BMI) of 40 or higher. Approximately 5 percent of Americans are morbidly obese. The morbidly obese surgical patient poses many unusual surgical/anatomical challenges during endoscopic laser minimally invasive spine surgery (MISS), and has a greater incidence of spinal surgical complications, up to 36% in spinal surgery, including problems with wound healing, pneumonia, deep vein thrombosis and need for further surgery. Other adverse outcomes and co-morbidities can include diabetes, kidney failure, hypertension, heart disease, liver disease, and nerve compressions. Newly developed GPS (grid positional systems) for MISS was designed to simplify and facilitate the endoscopic MISS, and microdecompressive spinal discectomy, especially for the morbidly obese. Materials and

**Methods:** Since 1995, 156 morbidly obese surgical patients with 254 symptomatic herniated lumbar discs underwent endoscopic MISS. Average age of 42 (20 to 67) with intraticable single and multiple lumbar herniated discs. Each failed at least 12 weeks of conservative treatment. They were safely treated with outpatient endoscopic laser MISS, guided and facilitate by application and utilization of newly developed GPS. Various endoscopic assisted tubular retractors, dilators, curettes, drills, flexible cutting forceps, saw-toothed trephines, and laser probes are utilized to perform transforaminal and posteromedial endoscopic lumbar microdecompressive discectomy and foraminoplasty for treatment of spinal stenosis. Holmium YAG laser is also applied for laser thermodiskoplasty.

**Results:** Overall result: 140 patients (90%) with good to excellent results. Fair results in 10 patients (6.4%), (with single level problem). For these 156 morbid obese patients, average follow-up, is 46 months (7-48 months). For single level, average satisfaction score is 93%, 145 patients. 11 patients 7% had mild residual pain and paresthesia, although overall their pain lessened. Complication rate is less than 1%. Average return to work is ten days

**Conclusion:** Endoscopic laser MISS, performed with GPS guidance, for microdecompressive lumbar discectomy and stenosis decompression in the morbidly obese surgical patient, is an effective, safe, less traumatic and easier spinal surgery. It avoids the more dangerous alternative of more traumatic open spinal procedures performed with general anesthesia. This less traumatic outpatient procedure reduces risk and complication, and leads to an excellent surgical result, faster recovery and significant economic savings.

**REFERENCES**

1.Chiu, J. Endoscopic Microdecompressive Lumbar Disc Surgery for morbidly obese - Medically High Risk Patients, 7th International Symposium on Minimally Invasive and Instrumented Surgery of the Spine Ukraine Academy of Medical Science, ISMISS/SICOT, Conference Syllabus, Kiev, Ukraine, May 30, 2009 2.Chiu, J. Session Chairman, on Endoscopic Transforaminal Surgery, introduction remark, Conference Syllabus, Rome Spine 2009, Tradition & Innovations in Spine Surgery, Rome, Italy, December 2-3, 2009 3.Katz JN, Stucki G, Lipson SJ, et al. Predictors of surgical outcome in degenerative lumbar spinal stenosis. Spine 1999;24:2229-33. 4.Khoo L, Fessler R. Microendoscopic decompressive laminotomy for the treatment of lumbar stenosis. Neurosurgery 2002;51(Supp 2):146-54. 5.Hijikata S. Percutaneous nucleotomy: A new concept technique and 12 years experience. Clin Orthop 1989;238:9-23. 6.Ascher PW, Choy, D. Application of the laser in neurosurgery. Laser Surg Med 1986;2:91-7. 7.Kambin P, Saliffer PL. Percutaneous lumbar discectomy: reviewing 100 patients and current practice. Clin Orthop 1989;238:24-34. 8.Chiu J, Savitz MH. Use of laser in minimally invasive spinal surgery and pain management. In: Kambin P (ed). Arthroscopic and Endoscopic Spinal Surgery Text and Atlas, 2d Ed. New Jersey: Humana Press, 2005, 25969. 9.Chiu J, Endoscopic Assisted Lumbar Microdecompressive Spinal Surgery with a New Smart Endoscopic System. In, Szabo Z, Coburg AJ, Savalgi

R, Reich H, Yamamotto M, eds. Surgical Technology International XV, UMP, San Francisco, CA 2006: p.265-275 10.Chiu J, Clifford T, Princenthal R, Junctional Disc Herniation in Post Spinal Fusion Treated with Endoscopic Spine Surgery: In, Szabo Z, Coburg AJ, Savalgi R, Reich H, Yamamotto M, eds. Surgical Technology International XIV, UMP, San Francisco, CA 2005: p.305-315 11.Onik G, Maroon J, Davis G. Automated percutaneous discectomy: A prospective multi-institutional study. Neurosurgery 1990;26:228-33. 12.Schreiber A, Suezawa Y, Leu HJ. Does percutaneous nucleotomy with discoscopy replaces conventional discectomy? Eight years of experience and results in treatment of herniated lumbar disc. Clin Orthop 1989;238:35-42. 13.Mayer HM, Brock M. Percutaneous endoscopic discectomy: Surgical technique and preliminary results compared to microsurgical discectomy. J Neurosurg 1993;78:216-25. 14.Savitz MH, Chiu JC, Yeung AT. History of Minimalism in spinal medicine and surgery. In: Savitz MH, Chiu JC, Yeung AD (eds), The practice of minimally invasive spinal technique. Richmond, VA: AAMISMS Education, LLC; pp 1-12, 2000. 15.Jaikumar S, Kim DH, Kam A. History of minimally invasive spine surgery. Neurosurgery 2002(Supp);51:1-14. 16.Knight M, Goswami A, Patko J, et al. Endoscopic foraminoplasty: An independent prospective evaluation. In: Gerber BE, Knight M, Seibert WE (eds). Laser in the musculoskeletal system. Berlin, Heidelberg, New York: Springer-Verlag Publishers; pp 320-9, 2001. 17.Savitz MH. Same day microsurgical arthroscopic lateral approach laser assisted (SMALL) fluoroscopic discectomy. J Neurosurgery 1994;80:1039-45. 18.Jaikumar S, Kim DH, Kam A. Minimally invasive spine instrumentation. Neurosurgery 2002;51(Supp 2):15-22. 19.Perez-Cruet M, Fessler R, Perin N. Review: Complications of minimally invasive spinal surgery. Neurosurgery 2002(Supp);51:26-36. 20.Destandau J. Endoscopically assisted microdiscectomy. In: Savitz MH, Chiu JC, Yeung AD (eds), The practice of minimally invasive spinal technique. Richmond, VA: AAMISMS Education, LLC; pp 187-92, 2000. 21. Chiu, J., Savitz, MH. Use of Laser in Minimally Invasive Spinal Surgery and Pain Management. In: Kambin P, ed. Arthroscopic and Endoscopic Spinal Surgery Text and Atlas. Second Edition. New Jersey: Humana Press; 2005: Chapter 13, pp 259-269. 22.Chiu J. Endoscopic Lumbar Foraminoplasty In: Kim D, Fessler R, Regan J, eds. Endoscopic Spine Surgery and Instrumentation. New York: Thieme Medical Publisher; 2004: Chapter 19, pp 212-229. 23.Chiu J, Clifford T. Transforaminal Endoscopic Decompression: In: Savitz M, Chiu J, Rauschning W, Yeung A, eds. The Practice of Minimally Invasive Spinal Technique: 2005 Edition, AAMISS Press, New City, New York, 2005: 60:p 435-441 24. Chiu J, Evolving Transforaminal Endoscopic Microdecompression for Herniated Lumbar Discs and Spinal Stenosis: In, Szabo Z, Coburg AJ, Savalgi R, Reich H, eds. Surgical Technology International XIII, UMP, San Francisco, CA 2004: pp. 276-286 25.Chiu J, Clifford T, Princenthal R. The new frontier of minimally invasive spine surgery through computer assisted technology. In: Lemke HU, Vannier MN, Invamura RD (eds), Computer assisted radiology and surgery, CARS 2002. Berlin: Springer-Verlag, pp 233-7, 2002. 26.Chiu J, Clifford T. Microdecompressive percutaneous discectomy: Spinal discectomy with new laser thermodiskoplasty for non extruded herniated nucleus pulposus. Surg Technol Int 1999;VIII:343-51. 27. Chiu JC, Hansraj K, Akiyama C, et al. Percutaneous (endoscopic) decompressive discectomy for non-extruded cervical herniated nucleus pulposus. Surg Technol Int 1997;VI:405-11. 28.Chiu JC, Clifford T, Greenspan M. Percutaneous microdecompressive endoscopic cervical discectomy with laser thermodiskoplasty. Mt Sinai J Med 2000;67:278-82. 29.Lin PM. Internal decompression for multiple levels of lumbar spinal stenosis: a technical note. Neurosurgery 1982;11:546-9. 30.Caspar W, Campbell B, Barbier C, et al. The Caspar microsurgical discectomy and comparison with a conventional standard lumbar disc procedure. Neurosurgery 1991;28:78-87. 31. Kambin P, Casey K, OBrien E, et al. Transforaminal arthroscopic decompression of lateral recess stenosis. J Neurosurg 1996;84:462-7. 32. Yeung AT, Tsou PM. Posterior lateral endoscopic excision for lumbar disc herniation: Surgical technique, outcome, and complications. Spine 2002;27:722-31. 33.Chiu JC, Clifford T. Multiple herniated discs at single and multiple spinal segments treated with endoscopic microdecompressive surgery. J Minim Invasive Spinal Tech 2001;1:15-9. 34.Knight M, Goswami A. Endoscopic laser foraminoplasty. In: Savitz MH, Chiu JC, Yeung AD (eds), The practice of minimally invasive spinal technique. Richmond, VA: AAMISMS Education, LLC; pp 337-40, 2000. 35.Clifford T, Chiu JC, Rogers G. Neurophysiological monitoring of peripheral nerve function during endoscopic laser discectomy. J Minim Invasive Spinal Tech 2001;1:54-7. 36.Chiu JC, Clifford T, Savitz M, et al. Multicenter study of percutaneous endoscopic discectomy (lumbar, cervical and thoracic). J Minim Invasive Spinal Tech 2001:1:33-7. 37.Clifford TJ, Chiu JC, Batterjee KA. Transpinal approach for endoscopic discectomy at L5-S1. J Minim Invasive Spinal Tech 2001;1:68-9.

# Full Endoscopic Operation With Interlaminar And Trans-/ Extraforaminal Approach Of Lumbar Juxtafacet Cyst –P rospective Randomized Controlled Study With 60 Patients

*Hahn P, Ruetten S, Komp M, Merk H, Godolias G*

*Department of Spine Surgery and Pain Therapy, Center for Orthopaedics and Traumatology, St. Anna-Hospital Herne, Herne, Germany*

**Introduction:** Juxtafacet cysts of the spine can cause radicular pain, neurological symptoms and are often associated with spinal degeneration. The mainstay of treatment of juxtafacet cysts is surgical resection with laminotomy and resection of the cyst. Other methods, including epidural steroid and facet injections are mostly temporarily effective. The aim of this study is the sufficient decompression with reduced traumatization and destabilization with the full-endoscopic interlaminar and transforaminal technique .

**Material and Methods:** 60 patients with unilateral, single-level juxtafacet cysts were included in this study. 30 Patients (group 1) were operated in full-endoscopic technique (22 interlaminar, 8 trans-/extraforaminal) and 30 Patients (group 2) with conventional microscopic-assisted technique. The full-endoscopic operation was performed with 6.9-mm endoscopes with 4.1-mm intra-endoscopic working canal. The follow-up was 18 months. 27 (91%) patients were followed. Additionally to general parameters validated scores were used.

**Results:** No intraoperative complications occurred. 2 patient in group 1 and 4 patients in group 2 showed transient dysaesthesia. The mean operation time in group 1 was 32 minutes, in group 2 56 minutes. There was no measurable blood loss in group 1, and a mean blood loss of 85 ml in group 2. The follow-up showed satisfactory subjective results in 53 patients. There were no significant differences between the two groups or within group 1 between the transforaminal and interlaminar technique in the clinical results. Group 1 showed significant advantages in different clinical, technical and economical parameters. The maximum time in hospital for group 1 patients was 3 days and 6 days in group 2. No recurrence of the cyst was found in the follow up.

**Conclusion:** The full-endoscopic operation of lumbar facet cysts with full-endoscopic technique is an alternative to the conventional microscopic-assisted procedure for sufficient decompression of juxtafacet cyst. It enables selective procedure with direct visualization, sufficient decompression and less traumatization of the access pathway and the spinal canal structures.

# Full-Endoscopic Posterior Foraminotomy For Operation Of Cervical Disc Herniations –P rospective Comparison to ACDF

*Ozdemir S, Ruetten S, Hahn P, Merk H, Godolias G*

*Department of Spine Surgery and Pain Therapy, Center for Orthopaedics and Traumatology, St. Anna-Hospital Herne, Herne, Germany*

**Introduction:** There are various techniques for the operation of cervical disc herniations. The most common today appears to be ventral decompression and fusion. It brings good results, but requires more major surgery with loss of segment mobility. Dorsal "keyhole foraminotomy" is also been used without fusion. This operation is now possible in a full-endoscopic technique. The objective of the prospective randomized study was to compare ventral decompression and fusion (Group 1) to full-endoscopic dorsal decompression (Group 2) in lateral, soft disc herniations.

**Material and Methods:** 70 patients were operated (35 per group). Inclusion criteria were: monosegmental mediolateral and lateral soft disc herniation, radicular pain. In Group 1, the operation was performed in known technique using a PEEK cage without plating. In Group 2, the operation was performed using 5.8-mm endoscopes with a 3.2-mm intraendoscopic working canal under continuous lavage. The follow-up lasted 24 months. 62 patients (88 %) were followed.

**Results:** The mean operation time in Group 1 was 75 minutes, in Group 2 35 minutes There were no measurable blood loss and serious complications in either group. In Group 1, 2 patients had transient difficulty swallowing. In Group 2, transient numbness occurred twice. There was no operation-related neck pain in Group 2 after wound healing. One patient in Group 2 suffered recurrence. CT-examinations showed resection of less than 1/4 of the facettes in Group 2. There was no increasing instability or kyphosing in Group 2, in Group 1 no adjacent instability. 57 patients subjectively attained a satisfactory result. This corresponded to the significantly constant improvement recorded by the validated measuring instruments. There were no significant differences between the groups.

**Conclusion:** Full-endoscopic dorsal foraminotomy is technically feasible and a potential alternative to ventral decompression and fusion. It enables a selective procedure with direct visualization, decompression is rapid, sufficient and the complication rate is low. Traumatization of the access pathway and the structures of the spinal canal is reduced due to the minimally-invasive technique. Strict attention must be paid to the indication for lateral and soft disc herniation. Recurrences cannot be ruled out.

# Full-Endoscopic Operations Of The Cervical Spine In Disc Herniations

*Sebastian Ruetten*

*Head Department of Spine Surgery and Pain Therapy, Center for Orthopaedics and Traumatology, St. Anna-Hospital Herne, Germany*

The therapy of degenerative diseases of the spine involves both medical and socioeconomic problems. A surgical procedure may be necessary if conservative measures have been exhausted and states of exacerbated pain or neurological deficits persist. Despite good therapeutic results with conventional operations, there may be consecutive damage due to traumatization. Thus, it is important to continuously improve these procedures. Taking existing quality standards into account, the objectives must be to minimize operation-induced traumatization and negative long-term sequelae. Current research results and technical innovations must be critically applied in order to guarantee the best-possible treatment strategies. Minimal-invasive techniques can reduce tissue damage and its consequences. Endoscopic operations under continuous fluid flow bring advantages which raise these procedures in many areas to the standard level. New optics have been developed with a wide working channel for spinal surgery which enable sufficient bone resection using burrs under visual control. These days, there are various full-endoscopic techniques available which can supplement each other. For the cervical spine, the anterior transdiscal and the posterior access are available. There are specific advantages and disadvantages for both techniques. The posterior access enables therapy of all lateral disc herniations. Unlike the anterior transdiscal procedure, which is the only treatment available for medial pathologies, the disc is not damaged and mobility is expanded. Considering the indication criteria, now the combination of full-endoscopic approaches with the new developed endoscopes and instruments provides sufficient decompression under visual control of cervical disc herniations. The results are equal to that of conventional procedures, but with advantages of a truly minimally-invasive procedure. However, total avoidance of known problems in spinal surgery can hardly be imagined. In addition, open procedures will remain as indispensable in the future as they currently are. At the moment the full-endoscopic procedures are estimated as a sufficient supplementation and alternative inside the complete spectrum of spine surgery.

# Anterior Endoscopic Microdecompressive Cervical Discectomy (AECD) with GPS

*John C. Chiu, M.D., Frcs, D.Sc*

*California Spine Institute*

**Purpose:** To demonstrate outpatient anterior endoscopic microdecompressive cervical discectomy and foraminal decompression (foraminoplasty), by utilizing GPS (grid positional system), can treat herniated cervical discs and cervical foraminal stenosis efficaciously and successfully, by mechanical decompression and application of lower level non-ablative Holmium laser for laser thermodiskoplasty (disc shrinking and tightening effect).

**Materials and Methods:** Since 1995, 2066 patients (3730 Discs), who failed at least 12 weeks of conservative care were treated. Levels were C2 to C7, inclusive. All patients demonstrated unilateral radicular pain of a specific dermatome, single level or multiple levels, confirmed with EMG/NCV. MRI or CT scans demonstrated the herniated cervical disc. The surgical technique of anterior endoscopic microdecompressive cervical discectomy foraminal decompression (foraminoplasty) and laser thermodiskoplasty (non-ablative lower Holmium laser energy for disc shrinkage) are described. The surgical approach guided and facilitated with GPS (grid positional system), is explained.

**Results:** For single level, 94% had good to excellent symptomatic relief and spinal motion preservation. 6% of patients had some persistent neck and upper extremity residual but diminished pain associated with parasthesia, after surgery. Average time to return to work was ten to fourteen days. At an average follow-up of 48 months. There were no intraoperative complications. Postoperatively, one patient with transient Horners syndrome and one transient hoarseness voice were noted.

**Conclusion:** The surgery of anterior endoscopic microdecompressive cervical discectomy and foraminal decompression with mechanical decompression and lower level non-ablative Holmium laser for disc shrinking and tightening effect (laser thermodiskoplasty) with GPS has proven to be safe, less traumatic, easier, and efficacious with significant economic savings. It preserves spinal motion. It is an effective alternative or replacement for conventional open cervical spinal surgery for discectomy, and can decompress foraminal stenosis, in degenerative spine disease.

**References:**

1.Chiu J, Endoscopic Assisted microdecompression of Cervical Disc and Foramen In, Szabo Z, Coburg AJ, Savalgi R, Reich H, Yamamotto M, eds. Surgical Technology International XVII, UMP, San Francisco, CA 2008: p.269-279 2.Ascher PW: Application of the laser in neurosurgery. Lasers Surg Med 2:9197, 1986 3.Bailey RW, Badgley CE: Stabilization of the cervical spine by anterior fusion. J Bone Joint Surg Am 42A:565569, 1960 4.Bernhardt M, Gurganious LR, Bloom DL, et al.: 3D magnetic resonance imaginganalysis of percutaneous discectomy. A preliminary report. Spine 18:21l217, 1993 5.Bonafe A, Tremoulet M, Sabatier J, et al.: Foraminal and lateroforaminal herniation. Mid-term results of percutaneous techniques for nucleolysis-nucleotomy. Neurochirurgie 39:110115, 1993 6.Bonaldi G, Minonzio G, Belloni G: Percutaneous cervical discectomy: Preliminary experience. Neuroradiology 36:483486, 1994 7.Castro WH, Halm H, Rondhuis J: The influence of automated percutaneous lumbar discectomy (APLD) on the biomechanics of the lumbar intervertebral disc. An ex- perimental study. Acta Orthop Belg 58:400405, 1992 8.Castro WH, Jerosch J, Brinkmann P: Changes in the lumbar disk following use of non-automated percutaneous discectomy. A biome-

chanical study. Z Orthop Ihre Grenzeb 130:472478, 1992 9.Castro WH, Jerosch J, Hepp R, et al.: Restriction of indication for automated percutaneous lumbar discectomy based on computed tomographic discography. Spine 17:12391243, 1992 10.Chiu JC, Hansraj K, Akiyama B, et al.: Percutaneous microdecompression discectomy for non extruded cervical herniated nucleus pulposus; Surg Technol Int VI:405411, 1997 11.Chiu JC, Clifford TJ, Negron F, et al.: Microdecompressive percutaneous discectomy: Spinal discectomy with new laser thermodiskoplasty for non-extruded herniated nucleus pulposus. Surg Technol Int VIII:343-351,1999 12.Chiu J, Clifford T, Greenspan M. Percutaneous microdecompressive endoscopic cervical discectomy with laser thermodiskoplasty. Mt Sinai J. of Med 2000;67:278-282. 13.Chiu J, Clifford T, Sison R. Anterior Endoscopic Cervical Microdiscectomy: In: Savitz M, Chiu J, Rauschning W, Yeung A, eds. The Practice of Minimally Invasive Spinal Technique: 2005 Edition, AAMISS Press, New City, New York, 2005: 54:p409-414 14.Chiu, J., Clifford, T. Cervical endoscopic discectomy with laser thermodiskoplasty. In: Savitz MH, Chiu JC, Yeung AT, eds. The Practice of Minimally Invasive Spinal Technique, AAMISMS Education, Richmond; 2000:141-148 15.Chiu J, Clifford T, Multiple herniated discs at single and multiple spinal segments treated with endoscopic microdecompressive surgery. J Minim Invasive Spinal Tech 2001;1:15-19. 16.Chiu J, Avoidance of Complications in Minimally Invasive Spinal Surgery. J Min Inv Spinal Tech; 3:1 pp 8-10, 2003 17. Chiu J, Digital Technology Assisted Minimally Invasive Spinal Surgery (MISS) for Spinal Motion Preservation. In: Lemke H.U, Vannier MN, Invamura RD, eds. Computer Assisted Radiology and Surgery. Amsterdam, San Diego, Oxford, London; Elsevier Medical Publisher; 2004, pp 461-466. 18.Chiu, J., Anterior Endoscopic Cervical Microdiscectomy. In Kim D, Fessler R, Regan J, eds. Endoscopic Spine Surgery and Instrumentation. New York: Thieme Medical Publisher; December 2004: Chapter 5, pp 48-58. 19. Cloward RB: The anterior approach for removal of ruptured cervical discs. J Neurosurg 15:602605, 1958 20.Cloward RB: The treatment of ruptured lumbar intervertebral discs by vertebral body fusion. J Neurosurg 10:1519, 1983 21.Fukushima T, Ishijima B, Hirakawa K, et al.: Ventriculofiberscope: A new technique for endoscopic diagnosis and operation. J Neurosurg 38:251256, 1973 22.Hijikata S: Percutaneous nucleotomy: A new concept technique and 12 years experience. Clin Orthop 238:923, 1989 23.Hirsch D: Cervical disc rupture: Diagnosis and therapy. Acta Orthop Scand 30:172176, 1960 25.Kahanovitz N, Viola K, Goldstein T, et al.: A multicenter analysis of percutaneous discectomy. Spine 15:713715, 1990 26.Key CA: On paraplegia depending on the ligaments of the spine. Guys Hosp Rep 7:17371739, 1838 27.Kotilainen E, Alanen A, Erkintalo M, et al.: Magnetic resonance image changes and clinical outcome after microdiscectomy or nucleotomy for ruptured disc. Surg Neurol 41:432440, 1994 28.Mixter WJ, Barr JS: Rupture of the intervertebral disc with involvement of the spinal canal. N Engl J Med 211:210215, 1934 29.Onik G, Maroon JC, Davis GW: Automated percutaneous discectomy: A prospective multi-institutional study. Neurosurgery 26:228231, 1990 30.Robertson YR: Anterior removal of cervical disc without fusion. Clin Neurosurg 20:259262, 1973 31.Robinson RA, Smith GW: Anterolateral cervical disc removal and interbody fusion for cervical disc syndrome. Bull Johns Hopkins Hosp 96:223224, 1955 32.Sherk HH: Lasers in Orthopaedics, JB Lippincott, Philadelphia, PA, 1990, pp 8590 33.Smith L: Enzyme dissolution of the nucleus pulposus in humans. JAMA 187:137-140, 1964 34.Smith L, Garvin PJ, Jennings RB, et al.: Enzyme dissolution of the nucleus pulposus. Nature 198:13111312, 1963 35.Stookey B: Compression of the spinal cord due to ventral extradural cervical chondromas. Arch Neurol Psych 20:275278, 1928 36.Ulrich HW: Automated percutaneous discectomy: Indication, technique and results after 2 years. Z Orthop Ihre Belg 130:4550, 1992 37.Yeo SJ, Tay BK: Clinical experience with automated percutaneous discectomy. Singapore Med J 34:313315, 1993 38.Zhou YC, Wang CY: Percutaneous lumbar discectomy using a new nucleotome system. Report of 182 cases. Chin Med J 106:446451, 1993 39.Zhou YC, Zhou YQ, Wang CY: Percutaneous cervical discectomy for treating cervical disc herniation-- a report of 12 cases. J Tongji Med Univ 14:110113, 1994

# Dorsal Endoscopic Rhizotomy of the dorsal ramus targeting the medial, intermediate and lateral branch for chronic nondiscogenic axial back pain

*Anthony T. Yeung, M.D., Yinggang Zheng, M.D., Christopher A. Yeung, MD*

*Desert Institute for Spine Care Phoenix, Arizona, USA*

**Introduction:** Radiofrequency lesioning of the medial branch of the dorsal ramus to the facet joint has been the standard approach specifically for facet joint mediated axial back pain. The efficacy of the procedure has come under recent scrutiny for effectiveness and surgical predictability. With better understanding of the microanatomy and pathogenesis of low back pain through meticulous fresh cadaver dissection, a posterior endoscopic method was developed to target lesioning of the medial, intermediate and lateral branches of the dorsal ramus responsible for innervation nondiscogenic axial back pain.

**Method:** A prospective non-randomized pilot feasibility study was initiated in 2006 to assess the effect of endoscopic radiofrequency lesioning of the dorsal ramus and its medial, intermediate, lateral branches on relieving chronic back pain. Patients who had evidence of degenerative disc disease, lumbar spondylosis, and facet arthrosis on MRI with predominant axial back pain were considered for treatment. Patients who had at least 50% improvement of their back pain with facet medial branch blocks were offered this endoscopic procedure. Modification of Richard Wolf's YESS cannula and a specially designed Ellman radiofrequency bipolar electrode were the surgical instruments utilized. Fifty patients were enrolled in the study from March, 2006 through June, 2007, then continued with refinements in the endoscopic technique for the next 50 patients.

**Results:** 48/50 from the pilot study had positive benefit from the rhizotomy at least equal to but mostly better than the pain relief they obtained with their medial branch facet injection. If relief from the first medial branch block resulted in less than 50% relief, or if the block gave only short term relief, the block was repeated until the patient indicated that they would be satisfied if they only had 50% long term relief. 10/50 has regressed but none were worse. While all had relief of back pain equal or greater than they had with the pre-operative block, many had relief of sciatica as well. Pre- and post-op VAS score decreased from 6.2 to 2.5 and Oswestry scores decreased from 48 to 28. No patient was worse. Extension of the study resulted in minor variations of the surgical exposure to dissect along the longitudinal plane between the multifidus and longissmus muscles. This allowed more aggressive identification and ablation of the lateral branches of the dorsal ramus, and the refinement of patient selection.

**Conclusion:** The basic science literature has identified the medial branch of dorsal ramus as the nerve supply to the facet joint. Many clinical presentations of non-discogenic low back pain also involve the dorsal ramus. For chronic low back pain, ablation of the dorsal ramus at L1 and L2 may relieve back pain two to three segments below, but the results are not as consistent as ablation at each anatomic level responsible for non-discogenic axial back pain. Medial branch injections at the transverse process identifies a source of low back pain that is amenable to endoscopic targeted lesioning that is more effective than traditional fluoroscopically controlled radiofrequency neurotomy. Compression of the spinal dorsal ramus is one cause of low back pain that is readily treated by this new technique. Lesioning of the branches of the dorsal ramus offers back pain relief in patients with lumbar spondylosis and facet arthrosis.

# Cure of lombosciatalgias, issues and prospects, intervertebral surgery and new trends, about the surgical techniques Percutaneous endoscopic transforaminal fusion with two cages (Pe-TLIF) uniportal and biportal?

*D. Gastambide (Paris), P. Moreau (Boursay, France), P. Finiels (N mes, France), F. Jacquot (Paris)*

Since 2005, as we showed here, we've inserted percutaneous cages for lumbar arthrodesis in "virgin spines" and in previously operated spines. Most of the first patients have been operated on in prone position. In the case of treating one disc by using an arthrodesis and one hernia on the level above on the same side in lateral position, we began to carry out the arthrodesis on only one side.

Seeing that the results on virgin spines were encouraging, 29 good primary results with a mean follow-up of 2 years on 39 patients, we wanted to simplify the technique by making a lateral approach and by using a more simple technique. In the case of one patient we put in two cages on the same side at every level, on L2L3 and L3L4 in the middle of the intervertebral space. For one other patient, we put in two cages in L3L4 through the same side. In the cases of three patients, we made a unilateral approach on L4L5 and put in two cages for two patients and one cage for the last patient. For one other patient, we put in two cages in L5S1. The immediate results were good.

We can't exactly explain why we can put in two cages for some patients and only one for others, particularly on the L4L5 level. Could this be due to the width of the Kambin triangle or to the number and the position of anastomosis between the exiting root and the white or grey ramus communicans of the sympathetic system which carries the nociceptive fibers? If the exiting root is painful while passing the dilators, we have a look at the endoscopic view of it and try to push it away without any pain. Then we pass the cage preceded by the dilators.

As a conclusion, we will show each case in detail and discuss the future of this technique.

# The Full-Endoscopic Interlaminar Versus Microsurgical Laminotomy Technique For Bilateral Spinal Decompression Of Lumbar Central Stenosis: A Prospective, Randomized, Controlled Study

*Hahn P, Ruetten S, Komp M, Merk H, Godolias G*

*Department of Spine Surgery and Pain Therapy, Center for Orthopaedics and Traumatology, St. Anna-Hospital Herne, Herne, Germany*

**Introduction:** Degenerative lumbar central stenosis with compression of neural structures may lead to clinical symptoms as neurogenic claudication with radicular signs. Spinal decompression can reduce symptoms of neurological deficits in lumbar spinal stenosis. In this respect, decompression, fusion or a combination of the two procedures are to be considered due to the possible leg and back symptoms. The use of microsurgical techniques has reduced tissue damage and its consequences. The goal of this prospective, randomized, controlled study was to compare the surgical results in degenerative lumbar central stenosis with full-endoscopic interlaminar bilateral technique with unilateral approach (FI) with those of a conventional microscopic-assisted technique (MI).

**Material and Method:** 160 patients with clinically-symptomatic degenerative lumbar central stenosis underwent surgical decompression. 80 Patients were operated in full-endoscopic interlaminar bilateral technique with unilateral approach in over-the-top technique (FI) and 80 Patients with conventional microscopic-assisted bilateral laminotomy technique (MI). Inclusion criteria were monosegmental central stenosis with predominant leg symptomatic, neurogenic claudication with or without paresis, back pain max. 20/100 on the VAS, conservative therapy exhausted or no longer indicated due to the symptoms. The full-endoscopic operation was performed with 9.9-mm endoscopes with 6.1 intra-endoscopic working canal. The follow-up was 24 months. 135 patients were followed. Additionally to general parameters validated scores were used.

**Results:** 72 % of the patients had postoperatively no longer leg pain or it was nearly complete reduced. 21.2 % had occasional pain. The clinical results were similar in both groups. The rate of complications and revisions was significantly reduced in the FI group. 11 Patients showed transient postoperative dysaesthesia (7 x MI, 4 x FI), 4 Patients had transient urinary retention (3 x MI, 1 x FI), Dura injuries occurred in 5 Patients (4 x MI, 1 x FI); 3 Patients (2 x MI, 1 x FI) showed a increase in preoperatively-existing foot dorsiflexion paresis. One Patient (MI) required revision because of epidural haematoma, 5 Patients delayed wound healing (5 x MI). Apart from transient dysaesthesia and transient urinary retention, the complication rate was 8.8 % (MI = 12,5 %, FI = 5 %) and was significantly higher in the MI group ($p < 0.05$). 4 patients (3 x MI, 1 x FI) required revision surgery due to persistent leg pain and/or progredient back pain, 3 (2 x MI, 1 x FI) of these additionally underwent fusion.

**Conclusion:** Within the indication criteria, the full-endoscopic interlaminar bilateral decompression with unilateral approach is a safe supplement and potential alternative to the conventional microscopic-assisted bilateral laminotomy-technique. The full-endoscopic technique shows advantages in the following areas: operation, complications, traumatisation, rehabilitation. It enables selective procedure with direct visualization, sufficient decompression and less traumatization of the access pathway and the spinal canal structures with all advantages of a minimally-invasive intervention.

# Intra-/Extraforaminal Lumbar Disc Herniation - Prospective Randomized Comparison Of Full-Endoscopic Technique With Trans-/Extraforaminal Access Versus Microsurgical Technique.

*Ozdemir S, Ruetten S, Hahn P, Merk H, Godolias G*

*Department of Spine Surgery and Pain Therapy, Center for Orthopaedics and Traumatology, St. Anna-Hospital Herne, Herne, Germany*

**Introduction:** Surgical management of intraforaminal and extraforaminal disc herniations may be more demanding than operation of intraspinal located pathologies, especially at the level L5-S1. The traditional microsurgery shows good result but problems can occur due to soft tissue damaging. The full-endoscopic operation of lumbar disc herniations inside the spinal canal is sufficiently feasible and a potent alternative to the microsurgical procedure. The objective of this prospective study was to compare the outcome of microscopic-assisted (group 1) with the full-endoscopic (group 2) decompression with trans-/extraforaminal approach in intra-/extraforaminal lumbar disc herniations.

**Material and Methods:** 40 patients underwent surgery in trans-/extraforaminal full-endoscopic technique and 40 patients with microscopic-assisted technique. Inclusion criteria were: single-level lateral disc herniation (intra-/extraforaminal), no central or lateral stenosis, no pronounced instabilities or deformities, unilateral leg pain, back pain max. 10/100 VAS. The full-endoscopic operation was performed under continuous irrigation with 6.9-mm endoscopes with a 4.1-mm intraendoscopic working canal. The follow-up was 24 months and included 72 patients. Validated measuring instruments were used in addition to general parameters

**Results**:6 patients in group 1 and 2 patients in group 2 presented transient dysaesthesia. The mean operation time in group 1 was 54 minutes and 21 minutes in group 2. The mean blood loss in group 1 was 85 ml, there was no measurable blood loss in group 2. The maximum time in hospital in group 1 was 7 days and 3 days in group 2. The follow-up showed satisfactory subjective results in 89 % with no significant differences between the two groups in the clinical resluts. This also corresponded to the constant results of the measuring instruments. The postoperative pain symptoms and rehabilitation were significantly reduced in group 2. Recurrence was found in 1 patient in group 1 and 2 patients in group 2 during the postoperative follow-up.

**Conclusion:** Within the indication criteria, the full-endoscopic operation of intra- and extraforaminal lumbar disc herniations is a potential alternative to the microscopic-assisted procedure and it is sufficiently feasible. It is a selective procedure with direct visualization. The decompression is found to be sufficient and the rate of complications is low. Traumatization of the access pathway and the vertebral canal is reduced und shows benefits particularly at L5-S1 compared to the microscopic-assisted procedure. The full-endoscopic operation has advantages with respect to economy and minimal invasiveness.

# Evolving Minimally Invasive Endoscopic Spine Surgery: A Surgeons Perspective And Emerging Technical Considerations

*John C. Chiu, M.D., Frcs, D.Sc*

*California Spine Institute*

Degenerated lumbar disc and spinal stenosis are common problems requiring decompressive lumbar surgery. Open spinal discectomy is associated with significant morbidity, long-term convalescence, prolonged general anesthesia and wide dissection of tissues that can cause bleeding, scarring and eventual destabilization of spinal segments. The evolving less traumatic minimally invasive endoscopic lumbar decompression procedure is free from these potential complications. Therefore the pursuit of minimally invasive spine surgery (MISS) began. The pioneering effort and innovative contributions were made by Lyman Smith, Hijikata, Parviz Kambin, Adam Schreiber, Hj. Leu, and others. This endoscopic spine surgical procedure, its surgical indications (for treatment of herniated lumbar discs, post fusion junctional disc herniation, neural compression, osteophytes, spinal stenosis, vertebral compression fractures, spinal tumor, synovial cysts and etc..), its operative techniques (both transforaminal endoscopic approach and interlamina endoscopic assisted approach) including tissue modulation technology (i.e. laser and radiofrequency surgical application) will be presented. With increased utilization of complex high tech and digital technologies, and instruments in the surgical suite, it requires seamless connectivity to perform the surgical procedures, in a precise and orchestrated manner. SurgMatix, a new integrated image-data based OR control system has been developed and utilized to facilitate this outpatient endoscopic spinal surgery. This system is designed to promote seamless integration of all aspects related to the surgical procedure and to reduce surgical time and personal requirement significantly. This ease to use SurgMatix system creates organized control instead of organized chaos. The surgical result has been extremely gratifying for both the patient and the surgeon. There was no postoperative mortality, and morbidity of less than 1%. However, the potential risk and potential complications will be discussed. Transforaminal endoscopic microdecompression can effectively decompress herniated discs and spinal stenosis with foraminoplasty for treatment of spinal stenosis. It also provides an excellent and effective access or platform for spine arthroplasty, spinal disk replacement, artificial disk, vertebralplasty, spinal fixation/fusion, disc re-growth technology and perhaps genome therapy. Obviously, this minimally invasive, less traumatic, outpatient endoscopic MISS treatment leads to excellent results, faster recovery, and significant economic savings.

**References:**

1.Savitz MH, Chiu JC, Yeung AT. History of Minimalism in spinal medicine and surgery. In: Savitz MH, Chiu JC, Yeung AD (eds), The practice of minimally invasive spinal technique. Richmond, VA: AAMISMS Education, LLC; pp 1-12, 2000. 2.Chiu J, Endoscopic Assisted Lumbar Microdecompressive Spinal Surgery with a New Smart Endoscopic System. In, Szabo Z, Coburg AJ, Savalgi R, Reich H, Yamamotto M, eds. Surgical Technology International XV, UMP, San Francisco, CA 2006: p.265-275 3.Chiu J. Endoscopic Lumbar Foraminoplasty In: Kim D, Fessler R, Regan J, eds. Endoscopic Spine Surgery and Instrumentation. New York: Thieme Medical Publisher; 2004: Chapter 19, pp 212-229. 4.Hijikata S. Percutaneous nucleotomy: A new concept technique and 12 years experience. Clin Orthop 1989;238:9-23. 5.Ascher PW, Choy, D. Application of the laser in neurosurgery. Laser Surg Med

1986;2:91-7. 6.Kambin P, Saliffer PL. Percutaneous lumbar discectomy: reviewing 100 patients and current practice. Clin Orthop 1989;238:24-34. 7.Schreiber A, Suezawa Y, Leu HJ. Does percutaneous nucleotomy with discoscopy replaces conventional discectomy? Eight years of experience and results in treatment of herniated lumbar disc. Clin Orthop 1989;238:35-42. 8.Destandau J. Endoscopically assisted microdiscectomy. In: Savitz MH, Chiu JC, Yeung AD (eds), The practice of minimally invasive spinal technique. Richmond, VA: AAMISMS Education, LLC; pp 187-92, 2000. 9.Chiu J, Evolving Transforaminal Endoscopic Microdecompression for Herniated Lumbar Discs and Spinal Stenosis: In, Szabo Z, Coburg AJ, Savalgi R, Reich H, eds. Surgical Technology International XIII, UMP, San Francisco, CA 2004: pp. 276-286 10.Chiu J, Clifford T, Princenthal R. The new frontier of minimally invasive spine surgery through computer assisted technology. In: Lemke HU, Vannier MN, Invamura RD (eds), Computer assisted radiology and surgery, CARS 2002. Berlin: Springer-Verlag, pp 233-7, 2002. 11.Chiu J, Clifford T. Microdecompressive percutaneous discectomy: Spinal discectomy with new laser thermodiskoplasty for non extruded herniated nucleus pulposus. Surg Technol Int 1999;VIII:343-51. 12.Chiu J, Stechison M, Percutaneous Vertebral Augmentation and Reconstruction with an Intervertebral Mesh and Morecelized Bone Graft: In, Szabo Z, Coburg AJ, Savalgi R, Reich H, Yamamotto M, eds. Surgical Technology International XIV, UMP, San Francisco, CA 2005: p.287-296 13.Chiu JC, Hansraj K, Akiyama C, et al. Percutaneous (endoscopic) decompressive discectomy for non-extruded cervical herniated nucleus pulposus. Surg Technol Int 1997;VI:405-11. 14.Kambin P, Casey K, OBrien E, et al. Transforaminal arthroscopic decompression of lateral recess stenosis. J Neurosurg 1996;84:462-7. 15.Chiu JC, Clifford T. Multiple herniated discs at single and multiple spinal segments treated with endoscopic microdecompressive surgery. J Minim Invasive Spinal Tech 2001;1:15-9. 16.Knight M, Goswami A. Endoscopic laser foraminoplasty. In: Savitz MH, Chiu JC, Yeung AD (eds), The practice of minimally invasive spinal technique. Richmond, VA: AAMISMS Education, LLC; pp 337-40, 2000. 17. Clifford T, Chiu JC, Rogers G. Neurophysiological monitoring of peripheral nerve function during endoscopic laser discectomy, J Minim Invasive Spinal Tech 2001;1:54-7. 18.Chiu J, SMART Endolumbar System for Microdecompression of Degenerative Disc Disease, presented at the Practical Course on Minimally Invasive Technique in Spinal Surgery, Russian Spinal Cord Society, Moscow Russia - April 26-29, 2007 19.Chiu J, Complications and Avoidance in Endoscopic Spine Surgery, presented at the North American Spine Society Minimally Invasive Spine Technique: Hands-on Course, Barrow Neurological Institute (BNI), Phoenix, AZ 20.Chiu J, Evolving Minimally Invasive Spinal Surgery (MISS) and Future Perspectives, presented at the Minimal Invasive Spinal Therapy SPINE, Seminar, Session; CARS 2007 Computer Assisted Radiology and Surgery 21st International Congress, Berlin, Germany. June 27-30, 2007 21.Chiu J, Digital Endoscopic OR Suite, In: Ed. Kyoko Yoshida, Views Radiology (Japanese), Tokyo, Japan: Medical Tribune, Inc., Vol 9-No. 3, 2007, ISSN 1881-1388, pp 20 22.Chiu J, Interspinous Process Decompression (IPD) System (X-STOP) For the Treatment of Lumbar Spinal Stenosis. In, Szabo Z, Coburg AJ, Savalgi R, Reich H, Yamamotto M, eds. Surgical Technology International XV, UMP, San Francisco, CA 2006: p.265-275

## Dr. med. Michael Schubert

Date of birth23rd february 1962

| | |
|---|---|
| Place of birth | Braunschweig |
| Family status | married |
| Address | Waldschulstr. 11c, 81827 Munich Germany |
| Nationality | German |

**Education and Qualifications**

| | |
|---|---|
| 1984 - 1991 | Medical study, Göttingen and Recife, Brasil |
| 1987 – 1988 | Scholarship in Brasil for the doctoral thesis, Institute for tropical medicine Göttingen, Germany (Prof. Dr. Bommer) |
| 1993 | Degree of doctor: „Seroepidemiologic Investigation of the prevalence of antibodys against Toxoplasma gondii in Recife and Borrelia burgdorferi in Recife and Fortaleza, Brasil“ |
| 1999 | Medical specialist in Orthopaedics |

**Employment History**

| | |
|---|---|
| 1992 – 1993 | Zürcher Hochgebirgsklinik, Intern Medicine (Davos, Swiss) |
| 1994 – 1997 | German Spine Center, Orthopaedy and spine surgery Werner Wicker Klinik, Bad Wildungen, Germany |
| 1997 – 2000 | Auguste Viktoria Klinik, Orthopaedy Bad Oeynhausen, Germany Juni 2000 – Sep. 2000, head of department for spine surgery |
| 2000 – 2002 | head of department, Orthopaedy and Traumatology, EuroMed Clinic Fürth, Germany |
| 2003 – 2008 | Senior spinesurgeon Alphaklinik Department Spine surgery (Dr. Hoogland), Munich Germany |
| 2008 | Foundation of the APEX SPINE CENTER, Munich Germany |

**Sciences**

| | |
|---|---|
| October 1987 | - scholarship (Federation of German science) |

**Oral Presentations**

| | |
|---|---|
| since 1989 | - multiple national and international presentations |

# Endoscopic Transforaminal Discectomy (ETD)

*Schubert, M, Helmbrecht, A.*

*Apex Spine Center*

**Background**

Microscopic dorsal lumbar discectomy is the gold standard treatment for lumbar symptomatic disc herniation. To reduce the complication rate and to eliminate the risks of general anaesthesia, more minimal invasive procedures gain significant interest in patients and spine surgeons. Purpose Of this study is to evaluate the effectiveness and complication rate of the endoscopic transforaminal discectomy (ETD) in all kinds of disc herniation whether far above or below the disc level.

**Study**

Design A prospective clinical study. Patient Sample 252 consecutive patients over a four year period with a MRI proven disc-herniation in the lumbar spine with radicular symptoms, positive Lasegue (<45), or neurological symptoms that did not respond satisfactory to conservative treatment off al least two months. Outcome Measures The patients had a clinical evaluation 3 months after surgery and returned at two years an extensive questionnaire including VAS Scores, MacNab Score as well as subjective satisfaction

**Methods:**

All patients were treated under local anaesthesia and could be discharged the day after surgery. From a lateral approach first the intervertebrale foramen was enlarged and a working cannula was inserted in the spinal canal. The prolapsed or extruded part was removed under endosopic vision with special forcepses, curettes and with an awl and a special reamer the inferior endplate was perforated, abraded and all loose intradiscal fragments were removed.

**Results:**

At the two year follow-up 96,4% of the patients reported an excellent or good result, 2,8% a fair and 0,8% unsatisfactory result. Patients reported a significant improvement in leg and back pain according to the VAS scale. According to MacNab criteria: 44,8% of the patients felt fully regenerated, 48,8 % felt their capacity slightly restricted, 5,6% felt they were noticeably restricted and 0,8 % felt unchanged. In 6 (2,4%)cases an early recurrent disc herniation (<3month) appeared. 3 patients (1,2%) had a temporary paraesthesia and foot weakness (which disappeared after 3 months). There were no cases of discitis. 13 patients (5,2%) were treated for recurrent disc herniation (between 3month and 2 years). 10 of those patients where treated endoscopically again, 3 had a microdiscectomy. 10 patients were very satisfied or satisfied after second surgery, one was unchanged and two were unsatisfied.

**Conclusion:**

The endoscopic transforaminal discectomy appears to be a safe, effective procedure without significant complications and is an alternative to open microdiscectomy.

Maghnia El Kasmi

Office Department of Spine Surgery and Pain Therapy
Center for Orthopaedics and Traumatology
St. Anna-Hospital Herne Hospitalstraße 19 44649 Herne Germany

Date of Birth December 02, 1977

**PROFESSIONAL HISTORY:**

| | |
|---|---|
| 1987 - 1993 | Academic High School, Gelsenkirchen Horst, Germany |
| 1993 - 1994 | Vocational education: Motor mechanic<br>Fiat/ Alfa Romeo, Gelsenkirchen, Germany |
| 1994 - 1997 | High School: General qualification for university entrance. |
| 1999 - 2006 | The University Essen – Duisburg, University medical center: license to practice medicine<br>Dissertation: Conventional and new digital methods in radiology clinical diagnostics by functional X-ray photography. |
| Since 12/ 2006 | Since December 2006 Resident Physician.<br>Department of Spine Surgery and Pain Therapy.<br>Center of Orthopaedics and Traumatology.<br>St. Anna-Hospital Herne, Germany |
| 08/ 2007 | Further Education: Emergency medicine, Department of Emergency medicine ,<br>Berlin Germany |
| 09/ 2008 | Vocational studies: Radiation protection,<br>Medical Association Westfalen Lippe, Münster, Germany<br>St. Anna-Hospital Herne, University of Witten/Herdecke, Germany |

Herne, 03.02.2010

# Full-Endoscopic Operation Of Lumbar Recess Stenosis Compared To The Microsurgical Technique

*El Kasmi M, Ruetten S, Hahn P, Merk H, Godolias G*

*qDepartment of Spine Surgery and Pain Therapy, Center for Orthopaedics and Traumatology, St. Anna-Hospital Herne, Herne, Germany*

**Introduction:** According to current knowledge, decompression reduces symptoms of neurogenic claudication and neurological deficits in lumbar spinal canal stenosis The extent of decompression and concurrent fusion are still controversial. The aim is sufficient decompression with reduced traumatization and destabilization. The goal of this prospective study was to compare initial results of the full-endoscopic (Group 1) to microsurgical (Group 2) decompression in degenerative lumbar recessus stenosis.

**Material and Methods:** 60 patients were operated in full-endoscopic lateral transforaminal (6 pats.) and interlaminar (24 pats.) or known conventional microsurgical (39 pats.) technique in 2004/2005. Inclusion criteria were: monosegmental unilateral recessus stenosis, no central stenosis, no disc prolapse, no pronounced instabilities or deformities, one-sided neurogenic claudication, back pain max. 10/100 VAS, positive nerve blockade. The full-endoscopic operation was performed with 6.8-mm endoscopes with 4.2-mm intra-endoscopic working canal under continuous lavage. There were specific inclusion criteria for the lateral transforaminal or interlaminar access. The follow-up period was 18 months. 55 patients (92 %) were followed. Validated measuring instruments were used in addition to general parameters.

**Results:** Intraoperative complications did not occur in any patient. One patient in Group 1 and 2 patients in Group 2 showed transient dysesthesia. The mean operation time in Group 1 was 42 minutes, in Group 2, 54 minutes. There was no measurable blood loss in Group 1, and a mean blood loss of 35 mL in Group 2. The maximum time in hospital in Group 1 was 4 days, and 6 days in Group 2. The postoperative pain symptoms as well as rehabilitation were significantly reduced in Group 1. The results revealed no or only occasional leg pain in 51 patients, 4 patients reported unsatisfactory results. The same was observed in lengthening of the walking distance. Radiological examination showed no increase in instability. The measuring instruments showed a significant, constant improvement on average. There were no significant differences between the two groups or within Group 1 between the two access pathways.

**Conclusion:** Within the indication criteria, the full-endoscopic operation of degenerative recessus stenosis is technically feasible and a potential alternative to the conventional procedure. It enables a selective approach with direct visualization, decompression is found to be sufficient and practically complication-free, the traumatization of the access pathway and the spinal canal structures is reduced. The questions of recurrence and stability cannot yet be definitively answered.

## Andrea Viviana Almeida Streitwieser

Sex: Female
Date of Birth: 23. Januar 1980
Place of Birth: Quito, Ecuador
Nationality: Deutsch, Ekuatorianisch
E-mail: a_andi@hotmail.com

Professional History Since March 2008 Residency at the Center for Orthopedics and Traumatology "St. Anna Hospital", Herne, Germanny Sept.

2006-Feb 2008 Residency at Konservativ Orthopedics at the "Katharina- Schroth Hospital" in Bad Sobernheim, Germanny Dec.2004–Nov.

2005 Residency „Hospital Alberto Correa" in Yaruquí, Ecuador Study Aug. 1998 – Sep

2004„ Universidad San Francisco de Quito" in Quito, Ecuador in Medicine Mai – Aug.

2003 Doctoral Thesis "Angiogenesis and vasculogenic mimicry in Ewing Sarcoma", at the Maastricht University in Maastricht, Neatherland.

# Full-Endoscopic Operation Of Lumbar Disc Herniation Versus The Microsurgical Technique. –24 Mo nths Results of a Prospective Randomized Comparative Study

*Almeida A, Ruetten S, Hahn P, Merk H, Godolias G*

*Department of Spine Surgery and Pain Therapy, Center for Orthopaedics and Traumatology, St. Anna-Hospital Herne, Herne, Germany*

**Introduction:** Full-endoscopic operation of lumbar disc herniations in transforaminal and interlaminar technique enables sufficient decompression. This technique can offer advantages over standard operations and can be an alternative to the microsurgical technique. Objective of this prospective study was to compare the outcome of full-endoscopic (Group 1) with microsurgical (Group 2) decompression in lumbar disc herniations.

**Material and Methods:** 90 patients were operated in full-endoscopic transforaminal (19 pats.) and interlaminar (26 pats) or microsurgical (45 pats.) technique. Inclusion criteria were: singlelevel disc herniation, no central stenosis, no pronounced instabilities or deformities, unilateral leg pain, back pain max. 10/100 VAS. The full-endoscopic operation was performed under continuous irrigation with 6.9-mm endoscopes with a 4.2-mm intraendoscopic working canal. There were specific inclusion criteria for the lateral transforaminal or interlaminar access. The follow-up was 24 months and included 92% of the patients. Validated measuring instruments were used in addition to general parameters.

**Results:** 2 patients in Group 1 and 1 patient in Group 2 presented transient dysaesthesia. The mean operation time in Group 1 was 23 minutes, in Group 2 42 minutes. There was no measurable blood loss in Group 1, the mean loss in Group 2 was 55 ml. The maximum time in hospital for Group 1 patients was 4 days and 6 days in Group 2. The follow-up showed satisfactory subjective results in 87% with no significant differences between the two groups. This also corresponded to the constant results of the measuring instruments. The postoperative pain symptoms and rehabilitation were significantly reduced in Group1.Recurrence was found in 3 patients in Group1 and 2 patients in Group 2 during the postoperative observation period.

**Conclusion:** Within the indication criteria, full-endoscopic operation of lumal disc herniations is sufficiently feasible and a potent alternative to the microsurgical procedure. It enables selective procedure with direct visualization, decompression is found to be sufficient and the rate of complications is low, traumatization of the access pathway and the vertebral canal is reduced.

**A. Sirenko**

Sex: Male

Date of Birth: 13th march 1967

Place of Birth: Kharkov (Ukraine)

Marital Status:

Nationality: Ukraine

Present Address: Pushkinskaya str. 80, Kharkov, Ukraine 61024.

E-mail: ipps-noo@ukr.net

Dr. A. Sirenko was born on 13th march 1967 in Kharkov (Ukraine). Internship was held in Kharkov municipal emergency hospital on the base of Kharkov National Medical University. He's been working in the department of spine pathology in Sytenko Institute of Spine and Joint Pathology since1999. He is a member of ISMISS from 2006, Ukrainian Association of Minimal invasive instrumental spine surgery from 2006. The Address: Sytenko Institute of Spine and Joint Pathology

# Diagnostic And Treatment Of After Lumbar Facet Joints Denervation

*V. Radchenko, A. Sirenko, I.Fedotova \ A. Sirenko*

*Sytenko Institute Of Spine And Joint Pathology, Kharkov, Ukraine*

Purpose of study is an increasing of prophylactic effectiveness of relapses after denervation of facet joints. Material and methods. In the group of patients (prospective investigation) we made diagnostic injection of facet joints and medial branch of spinal nerve in order to determine possible reinnervation. The result was indication fo redenervation of facet joints. After, we used the method of determination of medial branches localization of spinal nerves, which led the impulses from facet joints. The denervation of facet joints was made in 162 patients, 99 patients we examined retrospectively and 63-prospectively. They all were treated at the department of spine pathology of Sytenko Institute of Spine and joint pathology. In the group of patients (prospective examination) the method to determine, the localization of medial branch of posterior ramus of spinal nerves was performed. This method helps us to determine the optimal position of active point of needle-electrode relatively to medial branch of posterior ramus of spinal nerve due to it sensor electrostimulation. Topography of medial brauch of posterior ramus of varies in persons, thus generally accepted, staudant electrode poits can not coincide in some cases, because of that the nerve will not damaged entirely. Topography of medial braunch of posterior ramus of spinal nerve varies especially in patients with deformation of lumbar spine (spondylolistesis, scoliosis, kyphosis, hyperlordosis) and after operative treatment at posterior approach. As compared to retrospective results of pervious technologies for denervation of facet joints and prospective effectiveness of improved technologies for prophylactic of facet joint syndrome, we should mention that the results have been improveal significantly. Conclusion. Suggested method is effective at spondiloarthalgia after facet joint denervation in patient with lumbar spine deformation, also at spondiloarthralgia after sugerical treatment of lumbar spine due to posterior approach.

## Andrey Popov

Sex: Male

Date of Birth: 1972/12/22

Place of Birth: Kharkov, Ukraine

Nationality: Ukraine

Present Address: Sytenko Institute of Spine and Joint pathology, Academy of Medical Science of Ukraine; 80, Pushkinskaya street, Kharkiv, 61020, Ukraine

E-mail: ibolokadze@yandex.ru

**Present Position:**

Sytenko Institute of Spine and Joint pathology, Academy of Medical Science of Ukraine; 80, Pushkinskaya street, Kharkiv, 61020, Ukraine

**Education:**

1996 graduated from Kharkov State Medical University. He has had seniority without interruption since 1988. From 1996 to 1998 held an intern at the base of the Kharkiv Regional Clinical Hospital trauma. Since 1998 he has been working at the Institute of Pathology of the spine and joints behalf of Professor Sitenko AMS Ukraine. In 2005 defended his dissertation on the topic: “Experimental and clinical substantiation of punctional vertebroplasty in patients with compression thoracic and lumbar spine fractures due osteoporosis”.

Popov Andrey is an author of 39 scientific papers, 6 declarative patents. Always has been actively involved with presentations at conferences, congresses, symposiums. He is the executor of 5 research publications that run clinic pathology of the spine.

Popov Andrey is a member of SIROT since 2005, serves as a Secretary of citizens’ associations on instrumental and minimally invasive spine surgery.

# Study Of Percutaneous Vertebroplasty In Osteoporosis Vertebral Compression Fractures Using Various Compositive Materials

*V.Radchenko, A. Popov/ A. Popov*

*Sytenko Institute Of Spine And Joint Pathology, Kharkov, Ukraine*

Purpose of study. To evaluate results of the percutaneous vertebroplasty with different compositive materials.

Methods used. 139 patients with osteoporotic compression fractures were undergone percutaneous vertebroplasty. All patients were treated at the department of Spine Pathology Sytenko Institute of Spine and Joint pathology. X-ray follow-up afte 6 months, 12 months. Summary of findings. Patient were treated by percutaneous vertebroplasty using compositive material, which consists of bone cement (80%) and bioactive ceramic (20%). 139 patients with osteoporotic compression fractures were undergone percutaneous vertebroplasty.

The results of the investigation show bone resorbtion around injected compositive material afte 6 months and bone in ofte 12 months post-up. Relationship between findings and existing knowledge: The results of the investigation show bone resorbtion around injected compositive material after 6 months and bone in ofte 12 months post-up.

Overall significance of findings: investigeter compositive materale poges osteoinductive action in vertebrl osteoporotic fractures

**Athanasios Giannakopoulos**

Sex: Male

Date of Birth: June 18, 1979

Present Address: Department of Spine Surgery and Pain Therapy Center for Orthopaedics and Traumatology St. Anna-Hospital Herne Hospitalstraße 19 44649 Herne Germany

E-mail: athagian@t-online.de

**PROFESSIONAL HISTORY:**

2000-2006 Faculty of Medicine at the University of Essen, Germany

Since 2007 Center for Orthopaedics and Traumatology, St. Anna-Hospital Herne, University of Witten/Herdecke, Germany Director: Georgios Godolias, MD, Prof

2009 Practice for emergency Medicine

# Interlaminar And Lateral Transforaminal Full-Endoscopic Operation Of Recurrent Lumbar Disc Herniations In Patients With Conventional Previous Operations.

*Giannakopoulos A, Ruetten S, Hahn P, Merk H, Godolias G*

*Department Of Spine Surgery And Pain Therapy, Center For Orthopaedics And Traumatology, St. Anna-Hospital Herne, Herne, Germany*

**Introduction:** Recurrences following operations of lumbar disc herniations cannot be completely avoided. The rates are up to 8%, depending on the operation technique. Revision is mainly more demanding as an increased risk of injury exists due to the cicatrisation with frequently occurs. For this reason, more extensive resection of osseous parts may be necessary in order to achieve scar-free areas. As a minimally-invasive alternative to conventional techniques, there is the possibility of operating disk herniations full-endoscopically. The objective of the prospective study was the comparison of a full-endoscopic (Group 1) with the microsurgical (Group 2) revision in recurrent lumbar disc herniations in patients with conventional previous operations.

**Material and Methods:** 40 patients with recurrent lumbar disc herniation after microsurgical operation were revised in the full-endoscopic interlaminar technique (12 times) and lateral transforaminal technique (8 times) or conventional microsurgical technique (20 times) in 2003/2004. Apart from specific inclusion criteria for the lateral transforaminal or interlaminar full-endoscopic approach, there were no technical exclusion criteria. All the patients had a MRI-diagnosed disc herniation and, after a free interval, new occurrences of leg pains. New 7 mm endoscopes with intra-endoscopic 4.2 mm working canal were used. Follow-up lasted 12 months. 39 patients (20 full-endoscopic, 19 microsurgical) could be followed. Additionally to general parameters validated scores were used.

**Results:** No patients suffered injuries to the dura or neural structures. 3 patients in Group 1 and 4 patients in group 2 had a transient dysaesthesia. The mean operating time in Group 1 was 29 minutes (33 minutes interlaminar, 24 minutes transforaminal), in Group 2 57 minutes. In Group 1, resection of osseous sections was not necessary in any cases, in Group 2 in 16 cases. The postoperative pain symptoms and rehabilitation were significantly reduced in Group 1. The results showed a satisfactory result subjectively in 91% of the cases, without significant differences between the two groups. This also corresponded to the constant results of the scores.

**Conclusion:** The full-endoscopic interlaminar and lateral transforaminal revision of the recurrent lumbar disc herniation in patients with conventional previous operations is an alternative to microsurgical procedure. Advantages can result from quicker operating times, reduced osseous resections and lower traumatisation with reduced postoperative pain and shorter rehabilitation. In particular, the transforaminal procedure enables reaching of the epidural space from ventral, avoiding the scars. The disadvantage is the technical impossibility of occlusion of injuries to the dura, which can always occur in preoperated patients.

# The Lumbar Interspinous Distraction, Stabilization (IDS) Decompression Devices, (Initial Experience Of A Comparative Study)

*Mohamed Mohi Eldin*

*Cairo University*

Many Interspinous Distraction Stabilization (IDS) Devices has been developed. The first interspinous implant for the lumbar spine was developed in the 1950s by Knowles. Owing to flaws in design, material, surgical technique and applied indications its use was abandoned. Several other IPD devices, with significant differences in designs, materials, surgical techniques and indications have appeared in the 1990s, some of which are beginning to be evaluated in controlled trials. Most of these implants are placed in the interspinous space to improve clinical outcomes after a discectomy.

# Endoscopic Transforaminal Discectomy For Recurrent Lumbar Disc Herniation

*Schubert, M, Helmbrecht, A.*

*Apex Spine Center*

**Background**

Recurrent herniation is a significant problem as scar formation and progressive disc degeneration may lead to increased morbidity after traditional posterior re-operation. The advantage of the ETD could be that there is no need to go through the old scar tissue. The disadvantage may be a long learning curve for the spinal surgeon. Purpose To review complications and results of the endoscopic transforaminal discectomy (ETD) for recurrent herniated discs.

**Study**

Design A prospective clinical study. Patient Sample 262 consecutive patients over a four year period with a MRI proven disc-herniation in the lumbar spine with radicular symptoms, positive Lasegue, numbness or adynamia in the leg that did not respond satisfactory to conservative treatment over 3 months. Previous surgery had been performed in our own centre in 82 cases, 180 patients had previous surgery performed elsewhere.

**Outcome Measures**

The patients had a clinical evaluation 3 months after surgery and returned at two years an extensive questionnaire including VAS Scores, MacNab Score as well as subjective satisfaction

**Methods**

First a discography of at least 2 levels was conducted. The prolapsed or ruptured part of the posterior disc segment was removed with special forceps and special curettes. The procedure was performed under local anaesthesia.

**Results**

At two years 85,7% of the patients rated the result of the surgery as excellent or good. 9,7 % reported a fair and 4,6 % patients an unsatisfactory result. Patients recorded an average improvement of their back pain of 5,7 points and 5,9 points of their leg pain on the VAS scale(1-10). According to Mac Nab criteria 30,7% of the patients felt fully regenerated, 50 % felt their efficiency to be slightly restricted, 16,8% felt their efficiency noticeably restricted and 2,5% felt unaltered. All patients had a 3-month follow-up where possible complications were registered. The complication included: 3 nerve root irritations and 6 (2,3%) early recurrent herniations (<3 month). There was no case of infection or discitis. 11 patients have been reoperated for recurrence, after 3 months and within 2 years ( 4,6%).

**Conclusion**

Endoscopic transforaminal discectomy appears to be an effective treatment with few complications and a high patient satisfaction for recurrent disc herniation

## Vasil Shimon

Date of birth: March 12, 1954

Place of birth: Danylovo, Khust region, Transcarpathian oblast, Ukraine.

Nationality: Ukrainian

Sex: Male

Cavil status:Married, 2 children

Workplace: General Surgery, Traumatology and Orthopaedy Department, Faculty of Medicine of the Uzhgorod National University, Ukraine

# Treatment Of Protrusion And Non-Sequestered Hernias Of Intervertebral Discs Using Diode Laser

*Shimon V.M., Pichkar I.J.*

*Uzhgorod National University, Faculty Of Medicine*

Low back pain is one of the oldest and one of the widespread human diseases, and nowadays its treatment is still a very topical problem. The average expenditure of U.S. budget on vertebrogenic radiculopaties makes up annually up to 100 billion dollars. And in Britain (the population is about 56 million people) 13.2 million working days are lost annually because of discogenic pathology of the spine The above causes of the problem are considered to be not only medical, but social as well. Study purpose. To analyse results of treatment patients with protrusion and non-sequestered hernias of lumbar intervertebral discs using diode laser 940 nm. Materials and methods. On the base of orthopedics clinic of Transcarpathian regional clinical hospital 64 patients (31 male and 33 female) with protrusion and non-sequestered hernias of lumbar intervertebral discs have been treated using percutaneous laser disc decompression (PLDD). Patients have been divided by their age: less than 30 years 16 patients, 31-40 years 12 patients, 41 50 years 17 patients, 51 60 years 15 patients, more than 60 years 4 patients. Illness duration before the operation held has been: less than 6 months 10 patients, 6-12 months 19 patients, 1-2 years 21 patients, more than 2 years 14 patients. By the level of destruction the division has been the following: L3-4 - 22 patients, L4-5 - 46 patients, L5-S1 - 41 patients. 64 patients have been defined to have the pathology of 109 intervertebral discs. To make indications for operation all the patients have been examined by orthopedic surgeon and neurologist. 35 patients have had radicular symptoms, and 29 patients have had distinct miotonic and pain syndrome. To clarify the diagnosis we have used magnetic-resonance tomography and computer tomography. PLDD of 1 disc was performed in 27 patients, 2 discs in 29 patients and 3 discs in 8 patients. We have used home diode laser Lika-hirurg with wavelength of 940 nm in our work. Indications for PLDD were the following: the presence of confirmed protrusion or non-sequestered hernias of intervertebral discs 6 mm or less with or without radicular symptoms and with or without light paresis (4 scores) on CT or MRT; pain syndrome; positive Laseque sign; absence of the effect after the conservative treatment for the period of less than 6 weeks. Experimental study. We have conducted the research of influencing of constant and modulated radiation modes of diode laser with wavelength of 940 nm on white rats` nail intervertebral discs. The results have showed, that the best influence for the tissue regeneration of nucleus pulposus has a low power laser radiation. Results. Pain syndrome has been assessed by visual analogue scale (Your 0-10). The effectiveness of treatment has been evaluated according to the modified Macnab criteria [6], where: excellent complete absence of pain or any other symptom, no limitations in movement, ability to return to normal work and activity; good patient is generally satisfied, reduction of pain, come back to work and usual daily activities, taking analgesics from time to time; satisfactory minor improvement of functional activity, ability to work is not restored, bad no improvement, existing radicular symptoms, there is a need for re-surgery; the worst clinical symptoms have become worse than before treatment. The next day after surgery pain symptom decreased from 7.2 to 4.2 points. 29 (of 35) of patients with neurological symptoms the day after the operation were characterised by: considerably decreasing area of destructed sensitivity or its recovery; as well as by increase of muscle strength. Patients were directed to out-patient treatment to the place of residence within 2-3 days after surgery. The period of stay in hospital was from 2 to 5 days. Patients were not recommended to take a sitting position for a month. Advance review has been conducted after 1, 3, 6 and 12 months. After 1 month, 62 patients have been examined, after 3 months 54 patients have been examined, after 6 months 41 patients, in 1 year 27 patients. Neurologic symptoms have been observed in 6 patients. Pain syndrome has averagely been 2.4 according to the visual analogue scale. According to the modified Macnab criteria in 12 patients have been defined to have an excellent result, 8 good, 4 satisfactory, 3 bad. Thus, the successful outcome has been defined in 20 patients (74%). Complications associated with surgery have not been observed in any case. Open surgery due to unsuccessful dermal laser vaporization has not been conducted. Conclusions. 1. Diode laser with wavelength of 940 nm is optimal for the realization of vaporisation of intervertebral discs. 2. According to experimental data, this type of laser provides the most pronounced reparative processes in tissues of the disc. 3. You must comply with strict indications and contra-indications for the use of this technique.

**Hussien El-Maghraby**

Sex: Male

Date of Birth: 18 May 1967

Place of Birth:

Marital Status:

Nationality: British

Present Address: Clifford Bridge Road, Walsgrave, Coventry, CV2 2DX, England

Phone: 0044 2476 965208 - FAX: 0044 2476 965112

E-mail: hussienelmaghraby@hotmail.com, hussien.el-maghraby@uhcw.nhs.uk

**University Education**

University/Medical M.B., B.Ch. 1984-1991 School Cairo University, Egypt

**Postgraduate Qualifications**

Faculty of Medicine Cairo University Egypt M.S., General Surgery Master of Science November 1994

General Medical Council PLAB September 1995

Royal College of Surgeons of Edinburgh FRCS (Ed) February 1999

University of Nottingham England M.D. Neurosurgery July 2001

European Association Of Neurosurgical Societies European Board in Neurosurgery (EANS) October 2002

Royal College of Surgeons Intercollegiate Specialty Board in Neurosurgery FRCS (SN)October 2007

# Minimal Invasive Surgery For Spinal Trauma: Outcome Of Percutaneous Vertebral Augmentation With Percutaneous Pedicle Screw Fixation

*H. El-Maghraby, S.M. Joshi, A. Ahad, H. Ellamushi, J. Yeh*

*Department Of Neurosurgery, University Hospital Coventry & Warwick And The Royal London Hospital, , United Kingdom*

**Objective:** The aim of this study was to prospectively evaluate the long-term outcomes following percutaneous vertebral augmentation and pedicle screw fixation of vertebral body compression fractures due to trauma.

**Methods:** Symptomatic patients with vertebral body compression fractures due to trauma were assessed with plain radiograph, computed tomography and magnetic resonance imaging with short tau inversion recovery (STIR) sequences. Of these, 38 patients (24 males, age range 19-48 years) underwent percutaneous vertebral augmentation with percutaneous pedicle screws fixation from August 2003 to January 2009. A total of 44 (38 single, 3 multiple levels) T11, T12 and L1 represent 90% of all the vertebral levels treated. Outcomes were the visual analogue scale (VAS) for pain, radiographic evaluations of height restoration, kyphotic and wedge angle corrections, and Oswestry Disability Index (ODI). These were measured post-operatively on day 1, week 1, months 1, 3, 6 and years 1, 2 and 3. Follow-up was from 2 months to 4.2 years.

**Results:** The mean reduction of VAS was 6.1 +/- 2... Mean anterior height correction was 12.0% with kyphotic angle correction of 5.5 degrees and wedge correction of 5.7 degrees. Mean reduction of ODI improved was 49 points +/- 4.5. One patient had asymptomatic cement extravasation, one had worsening of vertebral collapse. There was no procedure-related mortality.

**Conclusion:** This minimally invasive procedure can provide long-term beneficial pain relief and improvement in functional outcome associated with radiological stabilisation of vertebral body height.

## Charis Matzaroglou

Sex: Male

Date of Birth:

Place of Birth:

Marital Status:

Nationality:

Present Address: Orthopaedics Department of Patras University University of Patras,

Medical School Ippokratous, Rio University Hospital Rio, Patras
Phone: +30 2610 999 551
FAX: +30 2610 994579
E-mail: orthopatras@yahoo.gr

# Monitoring Anaesthesia Control During Kyphoplasties

*C. Donados, M. Karanikolas, P. Kaspis, A. Saridis, C. Matzaroglou*

*Department Of Orthopaedics, Medical School, University Of Patras*

**OBJECTIVES:**

The risks associated with the procedure of kyphoplasty are low, but serious complications can occur as seen in the literature. These risks include spinal cord compression, nerve root compression, venous embolism, and pulmonary embolism including cardiovascular collapse. The purpose of this study was to observe all the parameters during the procedure under MAC (Monitoring Anaesthesia Control).

**DESIGN AND METHODS:**

Thirty-four (34) patients (58 vertebras) underwent 38 percutaneous kyphoplasty sessions between July 3, 2005, and February 4, 2008 time period. Causes thought to have been responsible for the vertebral body fractures in the patients treated, were: multiple myeloma (n = 12), osteoporosis (n = 11), metastatic disease from breast cancer (n = 4), lung cancer (n = 5), prostate cancer (n = 2). Twenty -three of these patients (23/34) had a history of malignancy and 12 had osteoporotic compression fractures. The maximum number of levels done in one setting was 3 (5 patients) With 16 patients having only 1 level intervened on, and 1 patient required 3 different settings. All patients underwent kyphoplasties in the operating room using biplanar fluoroscopy under local monitoring anaesthesia control (MAC). The mean age was 77.4 years. All patients were assessed with MAC during procedure and 30 minutes after. Also assessed , and then followed up after one, three and six months with Oswestry scale index.

**RESULTS:**

In all patients we observe decreased PO2 (5mmHg) ($p<0.005$) after cement placement and more than 7mmHg after the second level placement in the same setting. Also after the third level of cement placement we have seen decreasing of more than 7mmHg (8.5mmHg). We also observe that in patients with multiple myeloma, the levels of PO2 are lower after cement placement compared with the other pathologies ($p<0.0003$). Twenty-seven patients (27/34) exhibited significant and immediate pain improvement, 5 patients (5/34) responded within 5-7 days. Daily activities improved by 70.58 % (24/34) on the Oswestry scale.

**CONCLUSION:**

The risks associated with the procedure are low, but serious complications can occur if we have more than two levels in the same setting. We propose that the risk/benefit ratio in this procedure appears to be favourable in carefully selected patients and not than more than three levels in the same session.

# Quality Of Life Anxiety And Depression Improved After Kyphoplasties For Metastatic Disease

*C. Donados, K. Assimakopoulos, P. Kaspis, S C. Matzaroglou*

*Department Of Orthopaedics, Medical School, University Of Patras*

**OBJECTIVES :**

The relationship between pain quality of life (QOL) anxiety and depression in cancer patients is complex due to the number and the diversity of factors that can influence pain anxiety, depression and QOL. The aims of this study of oncology patients was focused only in thoracolumbar bone metastasis before and after kyphoplasties.

**DESIGN AND METHODS:**

We determine the pain characteristics (severity, duration, meaning of pain, physical functioning, social functioning) with Euro Qual, psychological distress (anxiety and depression), with HADS (Hospital Anxiety and Depression Scale) and determine which of these variables improved after kyphoplasties. A total of 47 oncology patients with bone vertebra metastasis completed questionnaires that evaluated pain, QOL, anxiety, depression, physical functioning, and social functioning. Pearson correlation coefficients were calculated to examine the relationships among the study variables.

**RESULTS:**

A multiple regression analysis was performed to determine which variables were the most important predictors of QOL of life and depression. Pain was significantly correlated with all the other variables, in particular pain intensity, depression and QOL The most important factors that predicted QOL were depression, social functioning, and physical functioning. Pain and Depression improved dramatically after kyphoplasties in a follow up of 6 months period in 91.58% (43/47).

**CONCLUSION:**

Kyphoplasty was a very effective technique for quality of life in vertebra metastatic disease.

## VIJAY GONI

Date of Birth: 17th February 1965

Nationality: Indian

Passport: G 7150817 Issued at Chandigarh on 5th February 2008 & valid till 4th February 2018

Address: # 1177 Sector-24B
Chandigarh 160023 (U.T.) INDIA

E-mail : vijaygoni@hotmail.com / vijayggoni@yahoo.com

Marital Status: Married to Dr Sapna Rani
6 year old daughter-Ms Urvi
6 month old daughter-Ms Yahvi

Registration: Karnataka & Maharashtra Medical Council
28101 (KMC) & 69794 (MMC)

# Retained, asymptomatic bullet in D11-D12 intervertebral disc space: A Case Report

*Vijay G Goni, Nirmal Raj, Sudesh Pebam, Naveen Tehashildar, Ashish Taneja and Vishal Kumar*

*Department of Orthopaedic Surgery,Post Graduate Institute of Medical Education & Research (PGIMER), Chandigarh 160012 INDIA.*

We report a 34-year-old police officer, who presented with low-velocity gunshot injury in his right flank.Neuroimaging localized the bullet in the Thoracic (D) 11-12 intervertebral disc space and neurological examination found no abnormalities. Patient is being managed conservatively, and is asymptomatic at thirty months of follow up till date.

**Keywords:** Bullet, Intervertebral disc space

**Introduction:** Gun shot injuries to the spine are mainly caused by suicides, accidents and assaults. These vary in proportion depending on the geographical location. Incidence of gunshot injuries perforating and being trapped within the spinal canal and intervertebral disc space is rare. Here, we present a case of gun shot injury with bullet in the intervertebral disc space with normal neurological status at presentation and at subsequent follow ups till date.

**Case report:** A 34-year-old, moderately built and nourished male police officer, working in the narcotics regulation department presented to the emergency room with low-velocity gunshot injury in his right flank region. The patient was conscious, and physical examination revealed no abnormalities except for entry wound of the bullet on his right flank, with no exit wound. Neurological examination was found to be normal.

Fig.1.Clinical photograph showing Fig.2 (a, b, c) Clinical photographs showing normal range of movements at Dorso -lumbar Spine Bullet entry site in right flank

Neuroimaging with X-rays and CT scan showed the bullet, located in the D11-D12 intervertebral disc space. All routine investigations were found to be within normal limits for his age and sex.The patient was discharged after 2 days of uneventful stay in the hospital.

Fig.3. Radiograph (AP & Lat.view) showing bullet in Fig.4.CT Scan showing bullet in D11-D12 Intervertebral disc space D11- D12 intervertebral disc space The patient on follow up till date showed no clinical symptoms or signs related to the bullet in the disc space. The repeat Radiographs and Computed Tomogram (CT) scan confirmed the bullet in its original position. Neurological examination is normal. Blood and urine lead levels are not raised.

**Discussion:** The damage caused by gunshot injury can be due to direct impact of the bullet or due to its projectile fragments injuring the spinal cord or indirect injury related to tissue damage caused in proportion to the kinetic energy and the velocity of the bullet. Most of the civilian injuries are due to low velocity gunshot injury and the military injuries are high velocity injuries with relatively greater magnitude of damage. Many reports about migration of bullet from para-spinal muscles and intervertebral disc space into the spinal canal exist in the literature. Conway etal1 reported a case of a bullet migrating from intervertebral disc space into the spinal canal.

The prognosis for subsequent improvement in neurological function and general condition is related with the level of spine affected. After a survey of 858 spinal cord injuries, Comarr etal2 concluded that cauda equine lesions recovered more frequently than spinal cord lesions. However, Yashon et al3 stated that the final outcome in spinal cord bullet injuries is correlated with initial neurological status rather than with surgery.

Our patient presented with a low velocity gunshot injury with bullet in the intervertebral disc space of eleventh and twelfth thoracic vertebrae and remained asymptomatic at follow up visits .Embedded bullets in the intervertebral disc may remain clinically silent through-

out life of the patients, however, it may migrate into the spinal canal or in the intervertebral disc space causing back pain and other pressure related symptoms1,4. Acute or chronic lead intoxication following bullet injury is uncommon; it can present with neurological, abdominal or hematological symptoms5. These incidences are rare and should probably not be used as a reason to remove all bullets. Bullet in disc space and joint is more likely to release heavy metals. Scuderi et al6 found only 12 cases of bullets in disc space over a 24-year period among 238 gunshot injuries of the spine and only 1 of these 12 developed clinical signs of lead toxicity. They recommend observation for signs of lead toxicity, rather than imperative bullet removal.

Surgical management for bullet injuries is widely accepted but conservative treatment is controversial7. Surgical indications for removal of the bullet, if embedded in the surrounding bone or in the intervertebral disc space is unclear. Bono and Heary8 reviewed the topic well and commented that; one should 'do no harm'. Removal of the bullet did appear to alter the rate and incidence of neurological recovery, but there was an increased incidence of infection in the operative group. Cornwell et al 9 reported on 141 thoracic spine gunshot fractures and only 2 required surgical stabilization. Removal of bullets remains controversial.

We recommend supervised neglect of patients with asymptomatic bullet/s in the intervertebral disc space and treatment of the patient in-toto rather than his/her radiographs/tomograms alone.

**References:**

1. Conway JE, Crofford TW, Terry AF, Protzman RR. Cauda equina occurring after a gun shot injury to the spine .A case report. J Bone Joint Surg Am 75:760-763, 1993.

2. Comarr AE, Kaufman AA. A survey of the neurological results of 858 spinal cord injuries. A comparison of patients treated with and without laminectomy. J Neurosurg, 13:95-106, 1956.

3. Yashon D, Jane J, White R: Prognosis and management of spinal cord and cauda equina bullet injuries in sixty-five civilians. J Neurosurg 32:163-170, 1970.

4. Davut C and Murat C; "Migration of a Bullet in the Lumbar Intervertebral Disc Space Causing Back Pain", Neurologia medico-chirurgica, Vol. 48, pp.188-190 (2008).

5. John BE, Boatright D: Lead toxicity from gunshot wound. South med J.92:223-224, 1999.

6. Scuderi GJ, Vaccaro AR, Fitzhenry LN, Greenberg S, Eismont F. Long-term clinical manifestations of retained bullet fragments within the inter-vertebral disk space. J Spinal Disord Tech 2004; 17: 108-111.

7. Heary RF, Vaccaro AR, Mesa JJ, Northrup BE, Albert JJ, Balderston RA, Cotler JM: Steroids and gunshot wounds to the spine. Neurosurg 41:576-584, 1997.

8. Bono CM, Heary RF. Gunshot wounds of the spine. Spine J 2004; 4:230-240.

9. Cornwell EE 3rd, Chang DC, Bonar JP, et al. Thoracolumbar immobilization for trauma patients with torso gunshot wounds: is it necessary? Arch Surg 2001; 136: 324-327.

**Farnad Imani, MD FIPP**

Date of Birth 11.02.1968

Work Address Department of Anesthesiology and Pain Medicine
Rasoul-akram Medical Center 145613131
Iran University of Medical Sciences (IUMS), 15875-6171
Tehran, Iran

Tel: (+9821) 66509059 - Fax: (+9821) 66515758

Cell phone: (+98911) 1305011

Email: farimani@iums.ac.ir

**Education**

1984-1992, Iran University of Medical Sciences (IUMS), Tehran, Iran: Medicine

1992-1995, Iran University of Medical Sciences (IUMS), Tehran, Iran: Anesthesiology

2008, Texas Tech University, Health Science Center, Lubbock, Texas, USA: Interventional Pain Procedures Observership

**Professional Training**

1992-1995 Anesthesiology Resident, Department of Anesthesiology, Iran University of Medical Sciences (IUMS),Tehran, Iran

2008, Texas Tech University, Health Science Center, Lubbock, Texas, USA: Interventional Pain Procedures Observership

**Professional Employment**

2007– present: Associate Professor & Head, Department of Anesthesiology and Pain Medicine, Iran University of Medical Sciences (IUMS), Tehran, Iran

1995-2007: Assistant Professor, Department of Anesthesiology and Pain Medicine, Iran University of Medical Sciences (IUMS), Tehran, Iran

# The Results Of Percutaneous Disc Decompression Utilizing Dekompressor In Patients With Chronic Lumbar Discogenic Pain

*F.Imani, Sr.Entezary, Mr.Alebouyeh, P.Rahimzadeh*

*Department Of Anesthesiology And Pain, Rasool-Akram Hospital, Iran University Of Medical Sciences (Iums), Tehran, Iran*

**Objectives:** Percutaneous disc decompression is a minimally invasive percutaneous procedure for treatment of low back pain and lower extremity pain due to herniated discs. The aim of this study was to evaluate the effect of Dekompressor on pain and analgesics consumption in patients with discogenic pain caused by herniated lumbar disc.

**Design and Methods:** In this prospective clinical study twenty-four patients with lumbar disc herniation, radicular pain resistant to medical treatment and physiotherapy for at least 3 months, and MRI-confirmed disc pathology correlating with the patient's symptoms (herniation<6 mm, with a disc height≥50% in comparison to normal adjacent discs) were included. All procedures were performed under local anesthesia and fluoroscopic guidance on an outpatient basis and were discharged within 12 hours. Visual analogue scale (VAS), analgesics consumption, and patients' satisfaction were evaluated at 2 and 6 months postoperatively. Data were compared between baseline and at 2 and 6 months after disc decompression.

**Results:** Twenty patients had one and four had two discs treated; a total of 28 procedures were performed. Pain score and analgesic consumption was stopped or reduced in 18 patients (75%) at 2 months and in 6 patients (25%) at 6 months after the procedure. Overall patient satisfaction was 70% at 2 months, and 91% at 6 months. There were no complications related to the procedures.

**Conclusions:** Disc decompression utilizing Dekompressor appears to be safe and effective for lumbar discogenic pain.

## Markus Ioannu

Sex: Male

Date of Birth:

Place of Birth:

Marital Status:

Nationality:

Present Address: General Hospital of Kimi P.Kiriakou 19 Athens - Greece

Phone: +306977872865

FAX: +302222022222

E-mail: markosioannou@yahoo.gr

# Efficacy And Safety Of Balloon Kyphoplasty-Are High Cement Volumes Required?

*M.Ioannou, G.Roumeliotis,E.Limaxis,O.Theodorou*

*General Hospital Of Kimi, Department Of Orthopaedic Surgery*

**BACKGROUND:**

Balloon kyphoplasty is a minimally invasive procedure for the treatment of painful osteoporotic vertebral fractures. Problems concerning adjacent level fracture and cement leakage are referred , both of which may depend on the volume and pressure of injected cement. In this study we aim to assess the efficacy and safety of the procedure.

**METHODS:**

Twenty adults with one to three vertebral fractures (total 31 fractures) w treated with balloon kyphoplasty were enrolled in this study. In all patients pressure of balloon expansion was not increased over 200psi. Cement volume per vertebra was 2,2 ml (1,5-2,9).Pre-and 6 and 12 months postoperatively the clinical parameters visual analogue scale and the Oswestry score and the vertebral height were evaluated. Mean surgical time was 31 min/level, mean hospital stay was 2 days.

**RESULTS:**

With a mean follow up of 12,4 months we had no perioperatively or other complications. The median pain scores (VAS) improved significantly pre-to 6 months posttreatment , as did the Oswestry disability score. All patients were satisfied regarding pain relieve and functional outcome even in cases were the vertebral body height was not reseted unexceptionably.We had no case of adjacent level fracture at 6 months postoperative time.

**CONCLUSION:**

Our findings suggest that balloon kyphoplasty is an effective and safe procedure for patients with osteoporotic vertebral fractures .Even in cases were restoration of the vertebral height was not satisfying, pain and disability scores improved pre-to posttreatment, even were low cement volumes are used.

# Six-Months Results Of Cervical Radiofrequency Ablation Neurotomy In Patients With Chronic Neck Pain

*M.Ioannou, G.Roumeliotis, E.Limaxis, O.Theodorou*

*General Hospital Of Kimi ,Department Of Orthopaedic Surgery*

**Aim:**

Cervical radiofrequency ablation neurotomy is a relative novel radiofrequency system for the treatment of chronic cervical pain due to degenerative arthritis. It aims to denervate the cervical facets. We present the results of 24 patients treated for painful degenerative cervical spondylosis with 6-month follow-up.

**Material-Methods:**

Twenty-four patients with chronic cervical facet joint pain >6months and evidence of degenerative arthritis of the cervical spine were enrolled in this study. Imaging Rx studies (face, profile and oblique) were available in all patients to establish diagnosis. Cervical radiofrequency ablation was performed under fluoroscopy using one to six radiofrequency probes positioned bilaterally at the cervical facets. All patients completed follow-up questionnaires at 6 months.

**Results:**

Twenty-one patients reduced drug use (NSAIDs or opioid drugs).Twenty patients were satisfied with the procedure, thirteen patients had completely relieve of their symptoms . No procedure-related complications were detected.

**Conclusions:**

Cervical radiofrequency ablation neurotomy services the trend of using smaller operative corridors. Whereas randomized controlled studies are warranted to address the efficacy of the procedure, six-months results of this method maintain that it is a save and easy to practice method for the treatment of chronic cervical facet joint pain. Patients showed improvements in several pain assessement measures after undergoing this method .

## Andrey E. Kobizev

Sex: Male
Date of Birth: 26 May 1968
Place of Birth: Russia
Marital Status:
Nationality: Russian
Present Address: The Turner Scientific and Research Institute for Children's Orthopedics, Parkovaya Str. 64-68, Pushkin, Saint-Petersburg, 196603 RUSSIA.

E-mail: andrey_kobizev@mail.ru

**EDUCATION**

1989-1995 - Medical high school.

1995-2000- Postgraduate trainee

2006 - Thesis for a Candidate's degree in Medical Sciences

**POSITIONS HELD**

2000-2009 Orthopedic Surgeon in The Turner Institute for Children's Orthopedics.

2009- up to present time Docent in the Medical Academy of Postgraduate Education, Department for Children's trauma and orthopedics

**WORK EXPERIENCE**

Performs more than 100 operations per year including;

- open and closed reduction in congenital hip dislocation;
- reconstructive operations on the spine, and thorax;
- microsurgery.

**PUBLICATIONS**

About 50 publications in leading Russian and foreign journals, proceedings and abstracts of surgical conferences on different aspects of children's trauma and orthopedics.

**PATENTS**

USSR/Russia 'Invention Certificates' – 6 invention certificates.

# Complications After Surgical Management Of Isiopathic Scoliosis In Children

*Andrey Kobizev*

*The Turner Research Institute For Children s Orthopedics, Saint-Petersburg, Russia*

**OBJECTIVES:** Study on complications after surgical management of idiopathic scolisis in children.

**MATERIAL & METHODS:** During last five years, 594 patients aged from 14 to 17 years with idiopathic scolisos of 3-4 degree were treated surgically in The Turner Institute for Childrens Orthopedics. In 340 patients from them, to obtain a fusion, operations on anterior vertebrae were carried out. From them, there were 294 thoracotomies and 47 lumbotomies.

**RESULTS:** During followup, 42 (14%) cases of hydrothorax were observed. Two patients needed repeated operations for inspection of a hemorrhage origin. In one patient a long fluid accumulation in pleural cavity was noted. It demanded more than three months for installation of drainage. There were no complications after surgical operation on lumbal spine.

**CONCLUSIONS:** We have concluded that the complication of hydrothorax may be related to an amount of surgical intervention.

# Percutaneous Endoscopic Transforaminal Lumbar Epidural Abscess Debridement And Drainage After Subarachnoid Hemorrhage; A Case Report

*Yorukoglu Ali Guven, Sencer Altay, Canbolat Ali, Kiris Talat, Sencan Fahir*

*Department of neurosurgery, Istanbul Medical Faculty, Istanbul University*

Epidural abscesses can be seen after spinal interventions or spontaneously via hematogenous spread. Surgical debridement and drainage of the abscess is an important part of the treatment. Percutaneous endoscopic transforaminal approach is a new, safe and effective treatment modality. A 62 year old male admitted to ER with complaints of sudden-onset severe headache, nausea and vomiting. Physical examination of the patient was consistent with neck stiffness; no other neurological deficit was identified. His past medical history showed lumbar disc surgery at the level of right L4-L5 10 years ago. Obtained cranial CT scan showed subarachnoid hemorrhage. The patient admitted to our neurosurgical clinic and cerebral digital subtraction angiography (DSA) obtained. There was no cranial vascular pathology except cerebral vasospasm seen in angiography. We performed whole spinal MR imaging which did not show any vascular pathology that can cause subarachnoid hemorrhage as well. We administered high-dose dexamethasone, antiepileptics and performed serial lumbar punctures. The patient was discharged after control cerebral DSA. 20 days later after the discharge the patient came back with severe low back pain radiating to his right leg. His neurological examination showed positive straight leg test on the right side. WBC count was 6900, CRP: 78.2, sedimentation 105mm/h. Visual analogue scale (VAS) was 9. MRI of the lumbar region showed epidural abscess at the level of L4-L5. We performed percutaneous endoscopic debridement and drainage of the abscess. Post-operative neurological examination revealed that straig leg test was negative, and VAS was 3. Post-operative early MRI showed that epidural abscess was drained successfully. Microbiological culture results came positive for methicilline sensitive staphylococcus aureus. 6 weeks of oral 2nd generation cephalosporin treatment is administered to the patient by infectious disease clinic. Percutaneous endoscopic transforaminal approach is an appropriate treatment modality in surgical interventions. It is a safe and minimally invasive procedure.

## Lester F Wilson

Sex: Male
E-mail: lesterfwilson@msn.com

1.Royal National Orthopaedic Hospital, Brockley Hill, Stanmore, Middlesex HA7 4LP
2.Welllington Hospital Spinal Unit, Wellington Place, London NW8 9LE

**Consultant Post:** I am currently working exclusively on Lumbar Spine Disorders using minimal access techniques for degenerative and pathological conditions.

**Training:** Orthopaedics and Spinal Surgery in Nottingham and London. Fellowship in Minimal Invasive Spine Surgery in Nottingham 1989-1990 [Prof RC Mulholland]

**Publications:** On Lumbar Spine disorders
I am on the advisory board for Apatech Ltd, a bone graft substitutes biotechnology company, and I work as teacher and trainer with Medtronic Ltd in Europe, where I am involved in the evolution of minimal access systems for the lumbar spine.

Since 2005 I have been the United Kingdom representative for the International Minimally Invasive Spine Society [ISMISS]. I am a member of the Spine Society of Europe, the British Association of Spine Surgeons and the British Orthopaedic Association.

# Unilateral Minimal Access Transforamenal Lumbar Interbody Fusion Surgery

*L. F. Wilson*

*Royal National Orthopaedic Hospital, Stanmore*

This study assesses the clinical and radiological efficacy of a unilateral approach [UTLIF] to achieve the surgical goal of fusing a motion segment where there is no requirement to correct a translational deformity

25 consecutive cases [age 36-89 years] had surgery between January 2006 and August 2008. 20 had radicular pain from unilateral collapse and neuroforamenal +/- lateral recess stenosis, and 5 cases had predominantly discogenic back pain without localised deformity. 5 cases had previously had surgery at the affected level, [4 decompressions,1 failed fusion].

The equipment used was the Quadrant retractor, Legacy polyaxial screws, Capstone cage [all Medtronic], and all patients had Silicated Hydroxyapatite graft inserted into and around the cage [Apatech]. Multislice CT scans were performed at 6 months and assessed by 2 radiologists independently.

Surgical time averaged 126 min [range 90-180 min, saving 46 mins compared to the bilateral approach], blood loss averaged 242ml [range 50-600 ml, saving 99 mls], no screws were malplaced [3.6% for bilateral approach]. Hospital stay for UTLIF was 1.8 days less.

4 patients had an additional operation; one cage migrated and was revised, three failed to fuse. The surgical goal was achieved in 84% and the clinical goal in 80%. Two cases had asymptomatic graft migration into the canal, and no case had significant cage subsidence or tilting, or screw loosening, even without a fusion.
This biomechanically weaker construct provided satisfactory fixation in all but one case. The savings in time and cost make it worthwhile in selected cases.

# Transforaminal Endoscopic Discectomy And Thermal Annuloplasty For The Treatment Of Discogenic Back Pain

*Rotim K, Saftic R, Lakicevic G*

*Clinical Hospital "Sisters Of Charity", Zagreb, Croatia*

**Purpose:**

We present our experience with transforaminal endoscopic discectomy and thermal annuloplasty for the treatment of discogenic back pain.

**Materials and Method:**

25 patients with single level of discogenic back pain were treated with transforaminal endoscopic discectomy and thermal annuloplasty like a first choice operation treatment. Patients were previously treated with physical therapy at least six month with no improvement. Discography was performed with all patients same as intraoperative discography with Indigo Carmine dye mixed with Omni Pack 1:5. All patients were operated by senior surgeon using transforaminal endoscopic approach at more painful side. The goal of operation was to identify and remove inflammatory disc and granulation tissue described by A. Yeung. The goal was achieved with 20 patients and at five patients we found foraminal disc herniation. Thermal annuloplasty was performed at all patients using bipolar flexible radiofrequency probe. Patients were examined three and six month after operation. Oswestry questionnaire and VAS scale tests were filled at control examination by all patients.

**Results:**

Out of 25 patients, 18 patients responded favorably to the Oswestry questionnaire, indicating significant improvement of their back pain greater than 60% on a visual analog scale. There was one superficial wound infection.

**Discussion and Conclusion:**

Treatment for non-radicular back pain is difficult despite all our knowledge and technology. Final solution is commonly fusion surgery but what to do with patients where fusion doesnt work? As a reasonable option we proposed selective endoscopic transforaminal surgery to our selected patients like a first choice minimal invasive treatment before fusion surgery. Out preliminary results and work of other authors convinced us that transforaminal endoscopic decompression combined with annuloplasty could be a first surgical step in process of treating discogenic low back pain.

# Minimally Invasive Ct Guided Trans-Foraminal Perineural Root Injection In Treatment Of Radiculopathy

*El-Maghraby H[1], Platts A[2], Bradford R[2]*

*1. University Hospital Coventry & Warwick, 2. Royal Free Hospital, United Kingdom*

**Objective:**
To assess the outcome of minimally invasive CT guided perineural root injection in treatment of radiculopathy

**Design:**
Retrospective chart review. Materials: 1312 procedures of CT guided trans-foraminal perineural root injections were enrolled between 2003-2009. Injection of 1mL of 40 mg of Triamcinolone Acetonide and 1 mL of 0.5% of Bupivacaine was given. Selection criteria for the 1st injection were pain persisting longer than 1 month, no objective neurological deficit, and radiological evidence of root compression of benign nature. Selection criterion for repeated injections was acute exacerbation of the previously known radicular pain.

**Outcome measures:**
Primary outcome measure was pain relief using visual analogue score at 6 weeks post injection.

**Results:**
1312 procedures were performed in 446 patients. 227 patients (51%) with cervical radiculopathy and 219 patients (49%) with lumbosacral radiculopathy. 85% had 3 injections, 6% had 2 injections, 3.3% had 1 injection and 4.7% had more than 3 injections. 72 patients (16%) had pervious spinal surgery. There was no root injury, 8 patients had wrong level injected and the procedure was repeated in later date and 10 patients had the procedure abandoned due to increased pain. 250 patients (56%) reported pain reduction of at least 50% in 1st injection. 331 patients (74%) reported pain reduction of at least 50% in subsequent injections during the acute exacerbation of the previously known radicular pain.

**Conclusion:**
Minimally invasive CT guided trans-foraminal perineural root injection in treatment of radiculopathy could be helpful, epically if given in acute exacerbation of pain, and should be included to the armamentarium of conservative management of radiculopathy

# Long Term Results Of Vertebral Augmentation In 260 Consecutive Pathological Vertebral Fractures

*H. El-Maghraby, S Joshi, A. Shad, M. Khan, C. Thakker, And J. Yeh*

*Department Of Neurosurgery, Department Of Interventional Neuro-Radiology, University Hospital Coventry & Warwick And The Royal London Hospital, United Kingdom*

**Background:**
Pathological vertebral fractures are associated with significant pain and disability. Vertebral augmentation has been gaining popularity in treating such conditions.

**Aim of the study:**
To evaluate the long term results of Precutanous vertebral augmentation

**Design of study:**
Prospective interventional cohort study

**Outcome measures:**
Visual Analogue Scale (VAS) for pain, Oswestry Disability Index (ODI) for daily activities, reduction of pain prescription medications and radiological effects as Vertebral Body Height Restoration, Kyphotic and Wedge angle corrections. Methods: From August 2003 to August 2009, 197 patients with 260 consecutive pathological vertebral fractures were enrolled.

**Results:**
198 patients with 260 pathological fractures were due to 55% tumours, 21 % osteoporosis and 24 % traumatic. Age ranged from 19-90 years with mean of 68 years. Follow up ranged from 6 months to 4.4 years with mean of 25 months. All patients sustained improvement of pain and reduction of disability with mean reduction of Visual Analogue Scale (VAS) of 5.7 (1.2) and mean reduction of Oswestry Disability Index (ODI) of 45 (5.5) ($P<0.001$). Pain prescription medications were stopped in 50%, reduced in 30%, unchanged in 16% and increased in 4% due to disease progression. The mean Anterior Vertebral Body Height Restoration, Kyphotic angle correction and Wedge angle correction were 6.6 %, 4.2 and 3.65 respectively. The main procedure related complications consisted of one symptomatic extra-vertebral cement leakage resulted in foot drop and required open decompression, one nerve root contusion with transient radiculopathy, one further collapse and one wound infection.

**Conclusion:**
Precutanous vertebral augmentation significantly improves pain and disability with maintained long term results.

## Levshin Alexander Anatolievitch

Of the senior researcher of the Sytenko Institute of Spine and Joint Pathology

Levshin Alexander, Higher Education, born in 1973, in 1997 graduated from Kharkov State Medical University, “Medical business”

He has had seniority without interruption since 1988. From 1997 to 1999 held an intern at the base of the Kharkiv Regional Clinical Hospital trauma.

Since 1999 he has been working at the Institute of Pathology of the spine and joints behalf of Professor Sitenko AMS Ukrainy.

In 2002 was adopted to graduate school of the Institute of Pathology of the spine and joints behalf of Professor Sitenko AMS of Ukraine, which he graduated in 2005 and defended his dissertation on the topic: “Structural and functional features and diagnosis of degenerative diseases of the lateral spine in people aged over fifty years”. Levshin Alexander is an author of 38 scientific papers, including 2 monographs, 6 declarative patents. Always has been actively involved with presentations at conferences, congresses, simpoziums. He is the executor of 5 research publications that run clinic pathology of the spine.

Alexander Levshin is a member of SIROT since 2003, serves as a Secretary of citizens' associations on instrumental and minimally invasive spine surgery.

# The Dynamic Interspinous U implant «Coflex» in the Treatment of the Degenerative Lumbar Spine Diseases

*Vladimir Radchenko, M.D.; Alexander Levshyn, PR.D.; Konstantin Popsuyshapka, PR.D.; Artem Skidanov, PR.D.*

*Sytenko Institute of Spine and Joint Pathology Academy of Medical sciences of Ukraine, Kharkov, Ukraine.*

**Purpose of study:** Is to reveal the peculiarities of surgical treatment of degenerative lumbar Spine diseases using dynamic interspinous U implant «Coflex».

**Methods used:** The material of investigation were 94 patients, who were operative undergoing treatment with the degenerative lumbar spine diseases, such as degenerative stenosis of vertebrae channel accompanied by neurogenic intermittens claudication (35 patients), degenerative spondylolistesis of the 1st stage (6 patients), disc hernias accompined by radiculopathy or radiculomyelopathy (44 patients), instability of vertebrae-motion segment (9 patients). All patients were treated at the department of spine pathology of Sytenko Institute of Spine and Joint Pathology.

**Summary of findings:** At the present time the implant «Coflex» is widely used. Due to «Coflex» we could provide an adequate treatment at minimal operative approach in patients with protrusions and hernias of vertebrae discs, degenerative stenosis of vertebrae channel, insignificant instability of vertebrae-motion segment and at the 1st stage of degenerative spondylolistesis. Implant «Coflex» can be placed at one and several vertebrae-motion segments. Also it can be used at $L_5$-$S_1$ segment at pronounced processes spinosus of $S_1$.

**Relationship between findings and existing knowledge:** using of dynamic interspinous U implant «Coflex» at different kinds of degenerative diseases of lumbar spine help us to safe mobility and stability in vertebrae-motion segment, to predict the decreasing of intervertebrae space of operated and adjacent vertebrae-motion segments, and to minimize the appearance of spondyloarthrosis.

**Overall significance of findings:** In order to get good results of surgical treatment we should follow the basic stages of operative technic and to apply this method according directly to indications.

# Interspinous Process Distraction Devices For The Treatment of Multilevel Degenerative Lumbar Spinal Stenosis

*G. Roumeliotis , M. Ioannou, E. Limaxis, O. Theodorou*

*General Hospital of Kimi, Department Of Orthopaedic Surgery*

**Background:** Interspinous Process Distraction Devices are designed for patients with symptomatic spinal stenosis .Many patients have stenosis in three or more level.

**Aim:** To assess the clinical outcome of patients with symptomatic multilevel lumbar spinal stenosis after ISPD implantation.

**Method:** Twenty five patients were enrolled and surgically treated with three level ISPD implantation. The device was implanted at the three more stenotic segments, which was L5-S1 48%, L4-L5 92%, L3-L4 88%, L2-L3 84 %, L1-L2 8%. .Mean hospital stay was 1,3 days. The clinical outcome was evaluated with use of a clinical questionnaire at 3 , 6 and 12 months p-op.

**Results:** 76% of the patients were satisfied with the procedure, 72% reported clinically significant improvement in their symptoms and 58% reported clinically significant improvement in physical function. We had no complications.

**Conclusion:** The results of this study indicate that ISPD offers significant short-term improvement in treatment of multilevel degenerative lumbar spinal stenosis. ISPD can be used safely in three levels.

**Konstantin S. Gordienko, PhD**

St-Petersburg State Hospital # 2
Uchebny per., 5, 194354
St-Petersburg, Russia
Phone: +7 812 5109407
Fax: +7 812 5107849
Mob. +7 921 3070022
e-mail: kgordienko@yandex.ru

## Current position:

Neurosurgeon, Department of Neurosurgery, St-Petersburg State Hospital #2, since 2000

## Education and qualifications

St-Petersburg Medical Academy of Postgraduate Education:

1. Postgraduate practical course - Chair of Neurosurgery 1998 - 2000
2. Postgraduate research study “Surgical treatment of trigeminal pain syndromes” – Chair of Neurosurgery, 2000 - 2003

Pskov Regional Hospital, neurosurgical training, Pskov, 1993-1994
Medical Institute, Leningrad, 1986-1993

## Professional organizations

St-Petersburg neurosurgical society – regular member
Russian Federation neurosurgical society – regular member
International Association for Study the Pain (IASP), since 2003

## Professional interest

Minimal invasive brain and spine surgery, treatment of orofacial pains syndromes, especially trigeminal neuralgia.

## Publications

38 in Russian language and 6 in English language journals.

# Foraminal Decompression At Patients With Cervical Radiculopathy And Radiculomyelopathy

*Konstantin S. Gordienko, Yuri A. Shulev, Marat N. Jusupov,*

*State Multifield Hospital #2 Medical Academy Of Postgraduate Education*

## Aim:

Evaluation of the clinical outcomes for patients undergoing anterior foraminal decompression (AFD).

**Material and methods:**

154 patients with cervical radiculopathy and radiculomyelopathy. There were 102 (66,2%) male and 52 (33,8%) female, mean age 51,7 (24-67). All the patients had lateral disk herniation with osteophytes. I group: 108 (70%) patients with radiculopathy (96 monoradicular syndrome, 12 biradicular). II group: 46 (30 %) patients. Radiculopathy was associated with moderate myelopathic syndrome. All patients underwent AFD (by Jho H.D., 1996) without instrumentation with uncus resection, sequestrectomy and with osteophytes resection. 142 (92,2%) patients underwent one-level decompression, 8 (5,2%) two-level unilateral decompression, 4 (2.6%) two-level bilateral decompression.

**Diagnostics included:**

neurological status, cervical radiographs (standard, 3/4 position and functional), MRI, electrophysiology. Pain syndrome was evaluated by visual analog scale (VAS), myelopathic syndrome by EMS index. Results: All patients were followed for a minimum of 12 month after AFD. Patients from I group had significant regress of radicular syndrome after surgery. Excellent results were at 92% (pain regress more than 80%), good at 8% of patients (pain regress 70-80%). Pain radicular syndrome regress at patients from II group has no significant differences from I group. Myelopathic syndrome regress was also estimated as good. EMS index preoperative showed 12,3+/-1,4 points; postoperatively 14,7 +/-1.9. Functional radiographs obtained at 3 months and 1 year after surgery indicated that none of the patients had evidence of delayed instability.

**Conclusion:**

AFD is an effective minimally invasive procedure. It appears to be a good alternative procedure to cervical decompression with fusion.

# Lumbar fusion gentle to other segments

*Sadaaki Nakai, Naoyuki Shizu, Shuntaro Hanamura, Shunzo Tsujimura, Makoto Nishio*

*Department of Orthopedic Surgery, Fujita Health University School of Medicine, Toyoake City, Japan*

It is generally considered that mechanical stress is concentrated on unfixed adjacent intervertebral discs and that degenerative change of the discs is accelerated after intervertebral fixation. However, when assessing the influence of intervertebral fixation on adjacent discs clinically, it should be considered that degenerative changes occur with aging and may also be related to various individual predisposing factors. Lumbar fusion is mainly done posteriorly, PLIF and TLIF, and both these operative methods have resembled character compared with anterior lumbar spinal fusion. We analyzed pre- and postoperative X-ray films after PLIF, and will mention about better intervertebral fusion to adjacent segments.

**Materials and Methods:** The subjects comprised 48 patients who had undergone PLIF of one or two discs more than 5 years previously, for a mean of 8.6 years. Measurement was performed using lateral radiographs taken in the standing position before surgery and at follow-up. Narrowing of the disc space, instability, and traction spur were checked.

**Results:** Narrowing of the disc space either proximal or distal to the fusion level was noted in 15 of the 48 patients (31%). Among these 15 patients, narrowing was seen at the disc just proximal to the fusion in 11 cases, at the disc distal to the fusion in 2 cases, and both proximally and distally in 2 cases. Narrowing of the disc spaces that were not adjacent to the fusion level was noted in 6 cases. New development of traction spurs was seen in two cases and the spurs increased over the preoperative size in seven cases at adjacent and nonadjacent segments, but almost always at the disc levels proximal to the fused disk.

**Discussion and Conclusion:** To assess the incidence of narrowing at adjacent disks after intervertebral fusion, we focused on patients with fusion at L4/5. Among our 48 patients, 37 had single fusion at L4/5. Among these 37 patients, narrowing or progressive narrowing of adjacent disk spaces was seen at 3/4 in 11 cases (30%), at L2/3 in 5 cases (14%), at L1/2 in 2 cases (5%), and at L5/S in 3 cases (8%). These findings suggested that the mechanical stress was mainly concentrated at L3/4 and L2/3 after fusion at L4/5. Theoretically, L5/S would be subjected to the greatest mechanical stress because it abuts the pelvis, as well as the greatest sagittal shearing force. When intervertebral fusion at L4/5 is necessary, the L5/S level has already been stabilized, and in consequence of the concentration of mechanical stress on the proximal segments. In the Japanese population, it was reported that intervertebral narrowing or progressive narrowing occurs at L3/4 in 24% and at l2/3 in 24% after follow-up of more than 10 years. In conclusion PLIF causes increased mechanical stress on the proximal segments, but degenerative changes of the adjacent segments are not marked. When we perform posterior intervertebral fusion in the lumbar area, we have to pay attention to the result of this clinical study.

# Combining Trans-Sacral, Lateral Trans-Psoas, and Percutaneous Pedicle Screw Instrumentation in the Lumbar and Sacral Spine.

***Burak M. Ozgur, MD.***

*Cedars-Sinai Medical Center, Department of Neurosurgery, Los Angeles, CA.*

Minimally invasive approaches to the lumbar spine continue to evolve in a quest to reduce approach-related morbidity. The lateral trans-psoas approaches are accepted as a safe and reliable technique through much of the lower spine, but cannot currently be performed at L5-S1 due to the iliac crest. Now, we propose that the trans-sacral approach allows a novel minimally invasive technique to access L5-S1. Additionally, the ribs used to be feared as a barrier to the lateral approach, but we will show that one can now safely perform the same lateral interbody fusion working in between the ribs working all the way up to the lower thoracic spine. Lastly, pedicle screw instrumentation is no longer a barrier in long segment instrumentation thanks to better developed percutaneous pedicle screw and rod delivery systems. We will describe these techniques used in combination to tackle multilevel cases including from the lower thoracic spine down to the sacral spine including adult degenerative scoliosis.

# The European Multicenter Trial For The Evaluation Of The Safety And Efficacy Of The Golif Spinal Instrumentation

*C. Birkenmaier, B. Wegener, V. Jansson*

*Department Of Orthopedic Surgery, Grosshadern Medical Center, University Of Munich*

**Background:**

The first 3 cases of transpedicular, transdiscal lumbosacral screw fixation in combination with a pedicle screw construct for isthmic spondylolisthesis were published by Abdu in 1994 [1]. Several small case series with similar constructs, some of them with additional transvertebral cages followed between 2001 and 2006 [2-7]. Grob (1996) was the first to present a series of 16 cases, in which direct transpedicular, transdiscal screw fixation of isthmic or degenerative spondylolisthesis without the use of an additional pedicle screw construct was successfully performed at the L4/5 and L5/S1 levels [8]. Zagra (2009) reported on a series of 62 patients operated on with the Grob technique for isthmic spondylolisthesis at the L3 through S1 levels [9]. Grob and Zagra both used additional posterolateral fusion and both had either 1 or 2 screw breakages in their series, but neither author observed pseudarthroses. The screw-related complications in these 2 series included inadvertent anterior cortical penetration, nerve root compression in the foramen and iliac artery compression, all requiring screw removal and repositioning. These complications already hint at the difficulty of safely drilling the transpedicular, transdiscal trajectories under fluoroscopy guidance with optimum screw purchase, but without compromising neural or vascular structures. The newly developed Guided Oblique Lumbar Interbody Fusion (GOLIF) procedure overcomes these problems by means of robotic-assisted navigation [10, 11]. It also expands on the original Grob procedure in 3 important ways: First, it makes minimally invasive, percutaneous screw placement possible. Second, it allows for the combination with intervertebral cage fusion techniques. And third, it doesnt require the presence of spondylolisthesis. These 3 factors greatly enlarge the range of possible indications. A multicenter study was designed to evaluate the safety and the efficacy of the GOLIF construct in clinical application.

**Method:**

Multicentric, non-randomized, prospective trial with 40 subjects. Patients between 18 and 80 years of age and an indication for the operative arthrodesis of a single lumbar or lumbosacral motion segment are eligible for inclusion. Exclusion criteria are true spinal deformities, lumbar hyperlordosis > 70 degrees, spondylolisthesis > 2nd degree (Meyerding), fractures, osteopenia or osteoporosis, inflammatory or malignant systemic diseases, status post irradiation, diabetes mellitus. Primary target criteria regarding safety are intra- and perioperative complications as well as the precision of implant positioning. Primary target criterion regarding efficacy is the execution of the procedure as planned preoperatively. A secondary target criterion regarding stability is the stability of the construct or the fusion, respectively, as evaluated on functional side-view plain X-rays at 12 months. Secondary target criteria regarding clinical improvement are the visual analog scale (VAS) for back and leg pain, the Oswestry Disability Index (ODI), the Short Form (SF) - 12 questionnaire and, depending on the indication, the Swiss Spinal Stenosis Questionnaire (SSSQ). This study protocol has been approved by the institutional ethics review board of the Ludwig-Maximilian-University, Munich.

**Results:**

Patient recruitment was begun in November 2009 and at the time of abstract submission, 2 patients have been

included. We expect that first results regarding safety will be available at the time of presentation. Discussion: This trial will for the first time assess the safety and efficacy of the GOLIF procedure in a prospective fashion in Europe. The results will be an indicator, whether this minimally invasive technique of spinal fixation may become an alternative for pedicle screw-based fixation in the future.

**References:**

**1.** Abdu WA, Wilber RG, Emery SE (1994) Pedicular transvertebral screw fixation of the lumbosacral spine in spondylolisthesis. A new technique for stabilization. Spine 19:710-715.

**2.** Chell J, Quinnell RC (2001) Transvertebral pedicle fixation in severe grade spondylolisthesis. Report of three cases. J Neurosurg 95:105-107.

**3.** Smith JA, Deviren V, Berven S, Kleinstueck F, Bradford DS (2001) Clinical outcome of trans-sacral interbody fusion after partial reduction for high-grade L5-S1 spondylolisthesis. Spine 26:2227-2234.

**4.** Boachie-Adjei O, Do T, Rawlins BA (2002) Partial lumbosacral kyphosis reduction, decompression, and posterior lumbosacral transfixation in high-grade isthmic spondylolisthesis: clinical and radiographic results in six patients. Spine 27:E161-168.

**5.** Francois J, Lauweryns P, Fabry G (2005) Treatment of high-grade spondylolisthesis by posterior lumbosacral transfixation with transdiscal screws: surgical technique and preliminary results in four cases. Acta Orthop Belg 71:334-341.

**6.** Beringer WF, Mobasser JP, Karahalios D, Potts EA (2006) Anterior transvertebral interbody cage with posterior transdiscal pedicle screw instrumentation for high-grade spondylolisthesis. Technical note. Neurosurg Focus 20:E7.

**7.** Kotil K, Tunckaya T, Bilge T (2006) Reduction of High-grade Spondylolisthesis Using a Transvertebral Surgical Approach in a Child. A Case Report and Review of the Literature. Turkish Neurosurgery 16:197-201.

**8.** Grob D, Humke T, Dvorak J (1996) Direct pediculo-body fixation in cases of spondylolisthesis with advanced intervertebral disc degeneration. Eur Spine J 5:281-285.

**9.** Zagra A, Giudici F, Minoia L, Corriero AS, Zagra L (2009) Long-term results of pediculo-body fixation and posterolateral fusion for lumbar spondylolisthesis. Eur Spine J 18 Suppl 1:151-155.

**10.** Lieberman IH, Togawa D, Kayanja MM, Reinhardt MK, Friedlander A, Knoller N, Benzel EC (2006) Bone-mounted miniature robotic guidance for pedicle screw and translaminar facet screw placement: Part I--Technical development and a test case result. Neurosurgery 59:641-650; discussion 641-650.

**11.** Sukovich W, Brink-Danan S, Hardenbrook M (2006) Miniature robotic guidance for pedicle screw placement in posterior spinal fusion: early clinical experience with the SpineAssist. Int J Med Robot 2:114-122.



## Jin-Sung Kim

- HP)82-10-8888-7514, e-mail) mddavidk@dreamwiz.com, md1david@wooridul.co.kr

**Education**

- Dec. 2007 Graduated with master degree in Catholic University Medical College, Seoul, South Korea
- Feb. 1997 Graduated with medical degree in Catholic University Medical College, Seoul, South Korea

**Job Experience**

- 5.1. 2000 ~ 2.28. 2001 Internship in St. Vincent Hospital
- 3.1. 2002 ~ 2.28. 2006 residentship at neurosurgical department in Catholic University **Medical Center**
- 3.2. 2006 ~ 2.28. 2008 fellowship at Wooridul Spine Hospital
- 3.2.2008 ~ consultant surgeon at Wooridul Spine Hospital in Chungdam, Seoul, Korea

**Special Achievement**

Best Fellowship Award, 2006, Wooridul Spine Hospital
Best Fellowship Award, 2007, Wooridul Spine Hospital
Good Oral Presentation Award, 2008, Wooridul Spine Hospital
Best Surgeon Award, 2009, Wooridul Spine Hospital

**Publications SCI(E)**

1. Kim JS, Lee SH, Moon KH, Lee HY. Surgical results of the oblique paraspinal approach in upper lumbar disc herniation and thoracolumbar junction. Neurosurgery. 2009 Jul;65(1):95-9; discussion 99.
2. Choi G, Kim JS, Lokhande P, Lee SH. Percutaneous endoscopic lumbar discectomy by transiliac approach: a case report. Spine (Phila Pa 1976). 2009 May 20;34(12):E443-6.
3. Kim JS, Jung B, Arbatti N, Lee SH. Surgical experience of unilateral laminectomy for bilateral decompression (ULBD) of ossified ligamentum flavum in the thoracic spine. Minim Invasive Neurosurg. 2009 Apr;52(2):74-8. Epub 2009 May 18.
4. Kim JS, Lee SH. Spontaneous spinal subarachnoid hemorrhage with spontaneous resolution. J Korean Neurosurg Soc. 2009 Apr;45(4):253-5. Epub 2009 Apr 30.
5. Kim JS, Choi KC, Jung B, Lee SH. Thrombosis of left common iliac artery following anterior lumbar interbody fusion: case report and review of literatures. J Korean Neurosurg Soc. 2009 Apr;45(4):249-52. Epub 2009 Apr 30.
6. Kim JS, Choi G, Jin SR, Lee SH. Removal of a discal cyst using a percutaneous endoscopic interlaminar approach: a case report. Photomed Laser Surg. 2009 Apr;27(2):365-9.
7. Kim JS, Kang BU, Lee SH, Jung B, Choi YG, Jeon SH, Lee HY. Mini-transforaminal lumbar interbody fusion versus anterior lumbar interbody fusion augmented by percutaneous pedicle screw fixation: a comparison of surgical outcomes in adult low-grade isthmic spondylolisthesis. J Spinal Disord Tech. 2009 Apr;22(2):114-21.

8. Choi KC, Kim JS, Jung B, Lee SH. Dynamic lumbar spinal stenosis : the usefulness of axial loaded MRI in preoperative evaluation. J Korean Neurosurg Soc. 2009 Sep;46(3):265-8.
9: Kim JS, Kim DH, Lee SH. Comparison between Instrumented Mini-TLIF and Instrumented Circumferential Fusion in Adult Low-Grade Lytic Spondylolisthesis : Can Mini-TLIF with PPF Replace Circumferential Fusion? J Korean Neurosurg Soc.2009 Feb;45(2):74-80. Epub 2009 Feb 28.
10: Seong JY, Kim JS, Jung B, Lee SH, Kang HY. CT-guided percutaneous vertebroplasty in the treatment of an upper thoracic compression fracture. Korean J Radiol. 2009 Mar-Apr;10(2):185-9. Epub 2009 Mar 3.
11: Kim JS, Choi G, Lee CD, Lee SH. Removal of discal cyst using percutaneous working channel endoscope via transforaminal route. Eur Spine J. 2009 Jul;18 Suppl 2:201-5. Epub 2008 Nov 26.
12. Kim JS, Lee SH. Carbon dioxide (CO2) laser-assisted ablation of lumbar discal cyst. Photomed Laser Surg 2009.10.01; 10 (1) :1-11.
13. Jin Sung Kim, MD., Seung Ho Yang, MD., Moon Kyu Kim, MD., Yong Kil Hong, MD. Cavernous Angioma in the Falx Cerebri : A Case Report J Korean Medical Sci 2006;21:761-4

**Literary Works**

Neurosurgery Board Review, 2006, first edition, Seoul Medical Book
Neurosurgery Board Review, 2007, second edition, Seoul Medical Book

# Pedicle Screw Fixation Under Navigation Guidance Based On O-Arm

*Jin-Sung Kim, Sang-Ho Lee, Jun-Seok Bae, Kyung-Chul Choi, Ji Young Cho, Ho-Yeon Lee*

*Department Of Neurosurgery, Wooridul Spine Hospital*

**Objectives:**

The purpose of this study is to describe a surgical technique and the accuracy of pedicle screw fixation under navigation guidance based on O-arm.

**Design:**

Prospective study

**Methods:**

Instrumentation using transpedicular screw fixation was performed using navigation guidance based on O-arm with 19 patients (78 screws). Evaluation of screw placement in every case was done on each instrumented vertebra by using intraoperative O -arm and plain X-ray. Screw placements were graded as good if the screws were placed in the central core of the pedicle and the cancellous portion of the body. Screw placements were graded as fair if the screws were placed slightly eccentrically, causing erosion of the pedicle cortex, and with less than a 2-mm perforation of the pedicular cortex. Screw placements were graded as poor if the screws were placed eccentrically with large portion of the screw extending outside the cortical margin of the pedicle and with more than a 2-mm perforation of the pedicular cortex, causing erosion of the pedicle cortex, and with less than a 2-mm perforation of the pedicular cortex.

**Results:**

1 patient was excluded due to connection error between O-arm and navigation. A total 72 pedicle screws were placed in 18 patients. 94.4% (68/72) were categorized as good; 5.6% (4/72), fair; and 0% were poor. All 4 fair screws were placed extending lateral margin of the pedicle without any neurologic complications.

**Conclusions:**

Aided by navigation guidance based on O-arm, surgeons can more safely navigate complex anatomy, and more accurately complete the procedure making this technology particularly helpful for pedicle screw fixation. This technique also makes complete avoidance of radiation exposure to surgeons while increasing accuracy and reliability of the surgical procedure for pedicle screw fixation.

# Anatomy Of Triangular Safe Zone Applied To Posterolateral Percutaneous Procedures

*Choi, Pil Sun, Basile Junior, Roberto*

*University of São Paulo – Brazil*

Submitted for presentation: (x) computer

**Study Design.** The triangular safe zone of L2-S1 was investigated by anatomic dissection of 100 foraminal levels in 14 human male cadaver spines.

**Objectives.** The goal was to best understand the triangular safe zone of Mirkovic et al. (1995) and to determine the boundaries, the format, the dimensions and the largest safe working cannula diameter.

**Summary of Background data.** Working cannula are used in percutaneous lumbar procedures. Mirkovic et al. defined triangular safe zone and determined the optimal cannula size and point of insertion in 1995. Based in their study, we decided to study the anatomy of lumbar foraminal zones applied in percutaneuos procedures.

**Methods.** Triangular safe zone dimensions from L2-L3 to L5-S1 were determined as was the inscribed circle (IC) diameter. IC was the maximal cannula size that can be placed within the safe zone.

**Results.** The height of triangular safe zone was formed by the lateral border of the thecal sac, not corresponding to the medial pedicular border; the base, by superior endplate of the inferior vertebra; and the hypotenuse by the spinal nerve. The average dimensions determined were: width 13.41 mm, height 21.68 mm, and hypotenuse 25.49 mm. The triangle formed like this is totally different from that described previously in the literature. In higher lumbar vertebrae (L2-L3 and L3-L4) approximately right-angled triangular safe zones were delineated, whereas in lower lumbar vertebrae (L4-L5 and L5 e S1), obtuse-angled triangular safe zones were delineated.

**Conclusion.** the triangular safe zone admits progressively larger external diameter working cannula from L2-L3 to L5-S1.

## Arvind Bhave

Sex: Male
Date of Birth: 1972, February 25
Place of Birth: INDIA
Nationality: INDIA
Present Address: Bhave Hospital,48,Parvati Industrial Estate, Pune-Satara Rd. Pune, Maharashtra India.411009
Phone: +912024225323

- Educational Training: Orthopaedic,&neurospinal.
- Master of surgery(orthopaedic surgery) (m.S.)University of poona, pune. India.1989.
- International postgraduate training course in medicine-orthopaedic surgery-tel aviv university telaviv (israel).-Spine surgery.1998.
- Fellow spinal injuries centre[fukuoka- [japan].2001.
- Fellowship – minimally invasive spine surgery-wooridul spine hospital –seoul – korea –2003.

**Present Position:**

- Professor of orthopaedics bharati vidyapeeth medical college. Pune India.

Patent for vertebroplasty needle device –under intelluctual property rights by ministry of commerce,govt. Of India.
Copyright & trade mark for the Vertebroplasty device.

**Books:**

1] Vertebroplasty made easy- Jaypees brothers Medical publishers.[September2008].
2] Emerging techniques in Spine surgery- [May2009] Jaypees brothers Medical publishers.

**Publications:**

Maharashtra Journal of Orthopaedic association-Percutaneous vertebroplasty.[2008] Chapter in Text book of Orthopaedics.

# Percuataneous Vertebroplasty-New Treatment For Osteoporotic Fractures Using Indiginous Instrumentation. AB Needle.

*Arvind Bhave*

*Bhave Hospital,48,Parvati Industrial Estate, Pune-Satara Rd. Pune, Maharashtra India.411009*

**Background:**
The vertebral compression fractures are diagnosed in large numbers because of increasing incidence of osteoporosis. They are treated conservatively with variable outcomes causing high morbidity due to deformities and pain. Minimally invasive spine surgery, by the way of vertebroplasty is good modality to stabilize the vertebral body to reduce pain and prevent long term deformity is getting acceptable, particularly in geriatric age group where major open surgeries are high risk.
**PURPOSE:** To study long term effectiveness of the 'Vertebroplasty' for osteoporotic vertebral fractures. To study usefulness of the indigenous instrumentation [AB NEEDLE] for vertebroplasty.

**Study Design:**
Retrospective study done over 4 years or more to study usefulness of the 'Vertebroplasty' particularly of geriatric age group patients. The geriatric patients are high risk for the extensive spine surgery, hence there is need for having Minimally Invasive methods to treat this osteoporotic population.

**Patient Sample:**
40 patients [27females and 13 males] in the age group of 60 to 90 years of age who had osteoporotic compression fractures were treated by 'PERCUTANEOUS VERTEBROPLASTY' studied for 6 years postoperatively. Study group patients were operated from the period of January2003 to December 2003 were analyzed. Locally made vertebroplasty needle device was used for all these cases. This device has been patented recently.

**Outcome Measures:**
The assessment was done as follows:
1] Subjective: pain relief and ability to do Activities of daily living [ADL].
2] Objective: VAS score [Visual Analogue score for pain], healing of the fractures on x-rays.
Patients were followed up 24 hours, 4 weeks, 12 weeks, 6 and 12 months and 48 months postoperatively.

**Methods:**
These 40 patients who had painful osteoporotic fractures ,who did not do well with conservative treatment, were high risk due to medical illnesses underwent percutaneous vertebroplasty using indigenously developed instruments. The history of the fractures was from 3weeks to 2 years and had progressive pain and deformity affecting ADL.

**Results:** All patients had significant improvement of VAS by 50% or more within 24 hours and activities of daily living started by next day. Good results were maintained even after 48 moths of the index surgery. There was no fresh adjacent level fractures.

**Conclusions:** The results of this series are comparable to the one-presented by2 MAC, kwok & Wong [2002]. Distinct advantages being:

1] All patients had excellent pain relief and all the fractures united.
2] Single day hospitalization or as a day care, local anaesthesia, less morbidity.
3] Reduction of cost by indigenous instrumentation.

Vertebroplasty is an excellent Minimally Invasive procedure for osteoporotic fractures of the geriatric patients.

## Shing-Sheng Wu

Sex: Male
Date of Birth: Jan. 25, 1953
Place of Birth: Taiwan, R.O.C.
Nationality: Taiwan
Present Address: No. 291, Jhongjheng Rd., Jhonghe City, Taipei Country 235, Taiwan, R.O.C.
Phone: (02) 2249-0088
E-mail: raysswu@gmail.com; raysswu@yahoo.com.tw

**Education:**

1972-1977 National Defense Medical Center, M.B. Taipei, Taiwan, R.O.C.
1977-1979 Rotatory Internship in Tri-Service General Hospital
2001-2003 Master of Medical Management Tulane University. USA

**Professional And Teaching Experience:**

Clinical appointments:
1981-1983 Residence in Surgery, Tri-Service General Hospital (T.S.G.H.)
1983-1985 Residence in Orthopaedic Surgery, T.S.G.H.
1985-1986 Chief Resident in Department of Orthopaedic Surgery(T.S.G.H.)
1986-1992 Attending Orthopaedic Surgeon, T.S.G.H.
1992-2001 Chief of General Orthopaedic Surgery. T.S.G.H.
2001-2007 Chairman of Department of Orthopaedic Surgery. T.S.G.H.
2004-2006 President of Taiwan Spine Society
2008- Chairman of Department of Orthopaedic Surgery. Taipei Medical University-Shuang Ho Hospital

**Faculty appointements:**

1981-1984 Assistant in Surgery, National Defense Medical Center
1985-1991 Instructor in Surgery, National Defense Medical Center
1989-1990 Fellow in Spine Research, SUNY Health Science Center Syracuse, N.Y.
1990-1990 Visiting Research Fellow Department of Orthopaedics, The University of Rochester, Strong Memorial Hospital N.Y.
1991-1998 Associated Professor of Orthopaedic Surgery, National Defense Medical Center
1998- Professor of Orthopaedic Surgery National Defense Medical Center
2004-2006 President of Taiwan Spine Society.
2006- Council member of Asian Pacific Orthopaedic Association. (APOA)
2006- Council member of Orthopaedic Association. ROC.
2006- Council member of Taiwan Osteoporosis Society.
2006- Council member of Pacific and Asian Society of Minimally Invasive Spine Surgery. (PASMISS)
2006- Council member of Asia Pacific of Orthopaedic Association. (APOA)
2010 President of Pacific and Asian Society of Minimally Invasive Spine Surgery. (PASMISS)
2010 President of the World Society for Endoscopic, Navigated and Minimal Invasive Spine Surgery. (WEN-MISS)

# Clinical evaluation and experience of IVEP in Vertebral Compression Fracture

***Shing-Sheng Wu, M.D., Hsieh-Hsing Lee, M.D .Po-Quang. Chen. MD. PhD***

*Department of Orthopaedic Surgery. .Shuang Ho Hospital,*

*Taipei Medical University, Taipei, Taiwan, Ming-Sheng. Hospital.. TaoYuan. Taiwan.*

Vertebral compression fracture (VCF) is a serious disaster arising from osteoporosis or trauma. Vertebroplasty and kyphoplasty are the common treatment strategies for vertebral body (VB) augmentation but reveal many complications. A newly designed implant should be considered for fracture healing and restoration of VB height, so we have developed an Intra-Vertebral Expansible Pillar (I-VEP®, Aaxter, Taiwan) to strengthen the collapsed VB. Totally, 52 cases were selected for this instrumentation since Jan 2006 to June 2009. The age ranged from 60 to 82 years old, and most of them were women. Surgery was done under general anesthesia and prone position. The pedicle screws were applied or not, and the I-VEPs are inserted to the collapsed VB via bilateral pedicles. The exact positions were checked by fluoroscopy. Posterolateral fusion was done with bone graft. The results revealed that all the patients had expected correction of kyphosis and restoration of the vertebral height. The intractable back pain also had been improved. The concept of I-VEP is like steel bar incorporating with cement for constructing a building. The larger size of I-VEP, the higher anterior support of VB will be accomplished. The expansible function maximizes the augmenting height of collapsed VB. The safe-zone concept ensures the intact inferior and medial cortex without injury of root and spinal cord.

The bursting fractures would be accepted in the lateral and superior cortex of pedicles. Augmentation by inserting expansible pillars and bone grafting is an acceptable alternative for treating the collapsed VB. The whole procedures could be performed via minimal invasive procedures under C-arm guidance.

# Cervical Multilevel Decompressive Fenestration: A New Surgical Technique For Cervical Spondylotic Myelopathy

*Cumhur Kılınçer, Umut Yaka, Altay Sencer, M. Inan Turantan*

*Trakya Universitesi Tıp Fakultesi, Norosirurji Anabilim Dalı, Edirne. Istanbul Universitesi Istanbul Tıp Fakultesi, Norosirurji Anabilim Dalı, Istanbul*

Lumbar discectomy is one of the commonest operation. Many discectomy cases show recurrent disc fragments without symptoms. This brings us the idea that bony decompression of the root (sometimes even without disc removal) may suffice. In this prospectively designed study, we evaluated results of a new technique.

**Method:** 21 patients (age range 33-67, mean 48) with radicular symptoms were operated on using the new technique called microforaminotomy. It consisted of 20-30 mm transverse skin incion on the symptomatic side centered on disc interspace; muscle dissection and application of Caspar retractor; and cretation of a hole (max 10 mm in diameter) on the lamina-facet junction of the cranial lamina using a high-speed drill under operation microscope. This hole generally well matched the location of the exiting root. In 15 cases, the hole itself was sufficient for decompression. In 6 cases, extruded disc fragments were found and removed. Preoperative and 1st month postoperative pain and disability scores were measured using visual analog scale (VAS) and Oswestry Disability Index (ODI).

**Result:** No complication was encountered. Patients were generally discharged next day. Pre- and postoperative VAS (mean 9.8 and 1.7 respectively) and ODI scores (64% vs 14%) showed significant improvements (P <0,001). 19 of 21 patients satisfied with the treatment.

**Conclusion:** Microforaminotomy method aims to decompress the root directly in a less invasive way. Hemipartial laminectomy, resection of the lig. flavum, and wide exposition of the local anatomy is not involved in this technique. Our results support that it may be an alternative technique in selected cases.

# Microforaminotomy: A New Surgical Technique For Lumbar Root Decompression

*Mustafa Kemal Hamamcioglu, Cumhur Kilincer, Levent Tuna, Sebahattin Cobanoglu*

*Trakya Universitesi Tip Fakultesi Norosirurji Ad*

Lumbar discectomy is one of the commonest operation. Many discectomy cases show recurrent disc fragments without symptoms. This brings us the idea that bony decompression of the root (sometimes even without disc removal) may suffice. In this prospectively designed study, we evaluated results of a new technique.

**Method:** 21 patients (age range 33-67, mean 48) with radicular symptoms were operated on using the new technique called microforaminotomy. It consisted of 20-30 mm transverse skin incion on the symptomatic side centered on disc interspace; muscle dissection and application of Caspar retractor; and cretation of a hole (max 10 mm in diameter) on the lamina-facet junction of the cranial lamina using a high-speed drill under operation microscope. This hole generally well matched the location of the exiting root. In 15 cases, the hole itself was sufficient for decompression. In 6 cases, extruded disc fragments were found and removed. Preoperative and 1st month postoperative pain and disability scores were measured using visual analog scale (VAS) and Oswestry Disability Index (ODI).

**Result:** No complication was encountered. Patients were generally discharged next day. Pre- and postoperative VAS (mean 9.8 and 1.7 respectively) and ODI scores (64% vs 14%) showed significant improvements (P <0,001). 19 of 21 patients satisfied with the treatment.

**Conclusion:** Microforaminotomy method aims to decompress the root directly in a less invasive way. Hemipartial laminectomy, resection of the lig. flavum, and wide exposition of the local anatomy is not involved in this technique. Our results support that it may be an alternative technique in selected cases.

# Spongioplasty a new Percutaneous Method - Technique, Indications and Results

*Haberland N.,*

*XCell-Center, Neurosurgical Department, Düsseldorf, Germany*

**Background**

The cement flow is difficult to check and control with conventional Vertebroplasty and the complications resulting may include leakages of the cement into the spinal canal. However the Kyphoplasty is more secure but the cost are very high. That's why we developed a new Technique which is standing between the Vertebroplasty and the Kyphoplasty.

**Methods:** With the Spongioplasty Concept, the loss of spongiosa and trabecula is more homogeneously balanced. For this purpose a percutaneous route in local or general anesthesia with the help of special access instruments is performed with a dorsal approach, pivotally transpedicular or extrapedicular, to the vertebral body. This is carried out under X-ray C-arm image control in 2 planes or optional with spinal navigation. The repositioning is made by corresponding ventral sag of the spinal column, when positioning the patient. With the instruments correctly placed a bilateral biopsy is taken by suction of spongiosa. This creates a cylindrical space (3mm x 3mm x 35 mm) in the vertebral body that allows for an optimal distribution of the bone cement.

Under X-ray C-arm image control the viscous bone cement is then delivered in the vertebral body by a special applicator. The cement (PMMA) hardens inside in a few minutes. Through this it comes to an interior stabilization of the bone and pain relief.

**Indications:** Fresh osteoporotic fractures of lumbar, thoracic and cervical spine, tumors and vertebral haemangioma.

**Results:** We have operated 109 patients, 80 female patients and 29 male patients. In the majority it was fresh osteoporotic fractures n= 97. Prae-operatively 91% of the patients had severe till unbearable pains and 92% of the patients had post-operatively non to moderate pains. A reposition could be obtained from at least 2° (2° to 8°) in 47.6% of the patients. Clinical relevant complications occurred in 0.9% of the patients.

**Conclusion:** Fresh osteoporotic fractures have a good follow up after percutaneous Spongioplasty.The Spongioplasty is a very safety and cost-effective method which biomechanical allows a good cement distribution. Furthermore we reached through the ventral sag position of the patient a repositioning of the vertebra fracture.

# Percutaneus kyphoplasty: Sun Yat-sen University experience in Guangzhou ,China

*Zhaomin Zheng M.D, Ph.D*

*Department of Spine Surgery, The First Affiliated Hospital, Sun Yat-sen University, Guangzhou, 510080, China*

From 2001 to 2009, we have treated over 250 cases with more than 400 vertebrae, including osteoporotic compression fractures, traumatic fractures and vertebral tumors with percutaneus kyphoplasty (PKP). As a result, we have summarized our experience into the following aspects.

**Indication of PKP**

The main indication of PKP is osteoporotic compression fractures and vertebral tumors with sever back pain. Pre-operative evaluation and patient selection are substantially important for prognosis. In our experience, rate of pain relief is higher than 90% with correct and strict surgical indication.

**Advantage of PKP vs. PVP**

PKP has lower cement leakage rate than PVP (percutaneus vertebraplasty) our patients. Balloon expansion provides a low pressure cavity inside the compressed vertebral body, which allows more sticky cement injection with lower pressure. It helps to control the cement distribution and extravasations.

**Unipedicular approach vs. Bipedicular approach**

Bipedicular approach is designed for even cement distribution in the vertebral body. However, it increases the cost, radiation exposure and operation time. In our experience, unipedicular approach with expanded abduction angle of punctuation is able to cross the midline of vertebral body and provide symmetrical cement distribution in more than 90% of our cases.

**Cement volumes of injection**

Literatures review has been reported that there is no significant relationship between clinical efficacy of PKP and the cement volumes of injection. In our experience, less than 3 ml cement in thoracic vertebrae and 5 ml in lumbar vertebrae are enough to receive satisfied pain relief and vertebral body height restore.

**Substitutes of bone filler materials**

PMMA, CPC and CSC bone cements are the three frequently used bone filler materials in PKP. In our experience, PMMA has more stable chemical and physical characters and is easier for injection. It is the first choice for old patients and patie nts with spinal tumors. CPC and CSC are selected for young patients because of its biological advantages.

**Control of cement leakage**

PKP expands the compressive vertebral body with hydraulic pressure provides a low pressure cavity for cement injection. However, expansion - cement injection is a two step procedure. We have developed a novel Vessel-X bone void filling container system and technique to create a one step procedure of expansion and cement injection. In our experience, using this system, the cement leakage rate is close to zero and the clinical efficacy is similar to traditional PKP.

# The Lateral Minimally Invasive Approach To The Lumbar Spine, One More Tool For The Spine Surgeon.

*Burak M. Ozgur MD.*

*Cedars-Sinai Medical Center Los Angeles, California*

The purpose of this study is to demonstrate the versatility and effectiveness of the minimally invasive lateral trans-psoas approach. Introduction: The minimally invasive lateral trans-psoas approach can be used in accessing the lumbar spine above L5 and the lower thoracic spine. We have used it repeatedly, safely, and effectively for common single level degenerative disc disease as well as multi-level adult degenerative scoliosis. It affords minimal side-effects and lends itself to much of the spine disease population. Patients tend to recovery very quickly and soft tissue is preserved especially in comparison to traditional open spine surgery. The minimally invasive lateral trans-psoas approach to the spine is a safe and effective technique used more and more by the spine surgeon. The advantages of minimally invasive surgery are appreciated and the outcomes are thusfar at least equivalent to traditional spine surgery.

# Minimally Invasive Surgeries To Treat Radiculopathy Caused By Lumbar Spondylolysis

*Koichi Sairyo And Akira Dezawa*

*Department Of Orthopedic Surgery, University Of Teikyo, Mizonokuchi Hospital*

**Introduction:**

We have developed 2 kinds of minimally invasive surgeries for the radiculopathy caused by lumbar spondylolysis using a spinal endoscope or percutaneous pedicle screw hook rod system (PSHR). Endoscopic decompression (ED) without fusion was indicated for aged patients with leg pain without instability and low back pain. Minimally invasive direct repair using percutaneous PSHR system after nerve root decompression was indicated for the active young adult with back pain and leg pain without instability.

**Methods:**

Total 9 patients were treated by ED surgery. Their mean age was 61.9 y.o. The endoscopic decompression including removal of the ragged bony edge and fibrocartilaginous mass was successfully conducted for all cases using a small skin incision (2 cm). The percutaneous PSHR was conducted for 10 patients aged between 32 to 55 (mean: 37). Following bilateral insertion of the percutaneous pedicle screws, the ragged bony edge and fibrocartilaginous mass was removed from the midline small skin incision (about 3 cm). The hook rod was connected to the pedicle screws and secured the pars defects. Cancellous bone graft was made through the midline skin incision. Biomechanical evaluation of the ED surgery was conducted using finite element (FE) technique as comparing to Gill laminectomy.

**Results:**

All but 1 patient who underwent the ED surgery, returned to the original activity within 3 weeks. For one case, pain did not decrease, and fusion surgery (L5/S) was conducted 5 months after the surgery. For remaining 9 cases, the clinical outcome was excellent or good. One out of 9 patients complained of leg pain at the contralateral side 3 years later. There was no evidence of further increase in slippage and instability for all the cases.

FE analysis showed 2-fold increase of the disc stress following the Gill laminectomy; however, the ED surgery did not change spine biomechanics after the surgery. It indicated that the ED surgery is the clinically and biomechanically minimally invasive.

Minimally invasive direct repair using percutaneous PSHR healed radiculopathy and low back pain for very active comparatively young patients. They returned the original job three months after the surgery when the defect showed tendency of the bony union.

**Discussion And Conclusion:**

For the surgical treatment of the radiculopathy caused by the lumbar spondylolysis, fusion surgery such as PLIF and TLIF was usually performed. The fusion surgery reduces the motion segment and has adjacent level problems. Therefore, it is very important for surgeons to consider motion preservation surgery as much as possible. In this paper, we have developed and introduced the minimally invasive surgery to treat the radiculopathy caused by lumbar spondylolysis which can preserve the motion segment. The technique was also minimally invasive and very effective to send back the patients to the original activity.

# Vertebroplasty Or Kyphoplasty: Which One To Choose?

*Mehmet Zileli, M.D.*

*Department Of Neurosurgery, Ege University Faculty Of Medicine, Izmir, Turkey*

**Headline:**

Compression fractures due to osteoporosis and osteoblastic tumors can be augmented with these techniques (vertebral augmentation). Vertebroplasty: Bone cement injection into compressed vertebral body. Kyphoplasty: Balloon inflation and bone cement injection into compressed vertebral body.

Indications are painful osteoporotic compression fractures and osteolytic metastatic tumors such as multiple myeloma. Contraindications are clotting disorders, painful situations not related to compression fractures, infection, insufficiant visualization, fractures that need stabilization, and bad general health condition.

**Method:**

Between August 2002 and February 2007 we have treated 75 patients with kyphoplasty technique. Indications were osteoporotic compression fracture (57), tumor related compression fracture (14) and traumatic compression fracture (4). Surgery was performed under general anesthesia (61 patients) or local anesthesia & conscious sedation (14 patients). Total number of vertebra treated is 103 (mean 1.4).

Surgical technique was percutaneous and bilateral transpedicular or unilateral extrapedicular needle insertion except one patient. Biplanar fluoroscopic control with one C-arm; verification of the needle first on lateral, then AP images, inflation of two balloons on each vertebral body with contrast media, high velocity acrylic was injected: 3 ml in thoracic, 5 ml in lumbar regions.

We also searched the literature to find out pros and cons of kyphoplasty and vertebroplasty.

**Result:**

More than 50% pain relief was achieved in all cases except one. There was no mortality and permanent morbidity. One patient had transient motor paralysis due to local anesthetic leakage to epidural space (spinal anesthesia). Paraspinal leakage of the cement is observed in 4 patients without any neurological or visceral compromise.

Kyphoplasty has advantages over vertebroplasty: Low rate of cement leakage, better technique to improve kyphotic deformity and lower rate of neurological complications. It is however, more expensive and may cause more radiation exposure.

More data are necessary to compare the two techniques in a prospective randomized fashion with standardized and validated methodology

# Kyphoplasty

*Altay Sencer*

*Istanbul Medical School Department Of Neurosurgery*

Percutaneous techniques for vertebral augmentation were first applied and reported in the late 80'ies in France to treat aggressive hemangiomas. Percutaneous injection of polymethylmethacrylate (PMMA) under high pressures into the involved vertebral body is called vertebroplasty. In the contrary, kyphoplasty involves an inflatable bone tamp causing a cavity filled with PMMA which is injected at lower pressures. It also causes some restoration of vertebral body height and spinal alignment. Both techniques provide marked pain relief with minimal complication rates.

This is also shown in our small series including 21 patients treated with kyphoplasty in the last three years in our clinic for various reasons like osteoporosis, tumor and trauma. The technique provided high patient comfort and no serious morbidity in the early postoperative period.

As conclusion, both techniques, vertebroplasty and kyphoplasty, are clearly efficacious treatments. But kyphoplasty, by creating a cavity and somewhat realigning the spine, appears to have significant advantages over vertebroplasty. It also minimizes the risk of cement leakage by compacting cancellous bone to the periphery and sealing off the fracture clefts and by creating a cavity in which cement is poured instead of injected by pressure.

# Balloon Kyphoplasty In Traumatic Thoracolumbar Fractures

*Cumhur Kilincer (*), Altay Sencer, Halil Can, Eysan Agabalayev, S. Murat Imer, Talat Kiris, O. Faruk Unal, Ali T. Canbolat, M. Inan Turantan*

*Trakya Universitesi Tip Fakultesi Norosirurji Ad, Istanbul Universitesi*

*stanbul Tip Fakultesi Norosirurji AD*

Lumbar discectomy is one of the commonest operation. Many discectomy cases show recurrent disc fragments without symptoms. This brings us the idea that bony decompression of the root (sometimes even without disc removal) may suffice. In this prospectively designed study, we evaluated results of a new technique.

**Method:** 21 patients (age range 33-67, mean 48) with radicular symptoms were operated on using the new technique called microforaminotomy. It consisted of 20-30 mm transverse skin incion on the symptomatic side centered on disc interspace; muscle dissection and application of Caspar retractor; and cretation of a hole (max 10 mm in diameter) on the lamina-facet junction of the cranial lamina using a high-speed drill under operation microscope. This hole generally well matched the location of the exiting root. In 15 cases, the hole itself was sufficient for decompression. In 6 cases, extruded disc fragments were found and removed. Preoperative and 1st month postoperative pain and disability scores were measured using visual analog scale (VAS) and Oswestry Disability Index (ODI).

**Result:** No complication was encountered. Patients were generally discharged next day. Pre- and postoperative VAS (mean 9.8 and 1.7 respectively) and ODI scores (64% vs 14%) showed significant improvements (P <0,001). 19 of 21 patients satisfied with the treatment.

**Conclusion:** Microforaminotomy method aims to decompress the root directly in a less invasive way. Hemipartial laminectomy, resection of the lig. flavum, and wide exposition of the local anatomy is not involved in this technique. Our results support that it may be an alternative technique in selected cases.

## Artem Skidanov

Sex: Male
Date of Birth: 1972, February 25
Place of Birth: Kharkov (Ukraine)
Marital Status:
Nationality: Ukraine
Present Address: Sytenko Institute of Spine and Joint Pathology Pushkinskaya str. 80, Kharkov, Ukraine 61024
E-mail: skidanov_artem@ukr.net

- Graduated from Kharkov State Medical University in 1998.
- Studied from 1998 – 2000 - postgraduate education of orthopedics and traumatology in Kharkov Medical Academy of Postgraduate Education.
- From 2000 – 2003 worked in the department of traumatology in Kharkov Municipal Multifield Hospital №18.
- 2003 – 2005 – Did clinical studies in Sytenko Institute of Spine and Joint Pathology.
- From 2005 – 2008 studied a postgraduate course in Sytenko Institute of Spine and Joint Pathology.
- 2008 – Received his medical sciences degree.
- The Dissertation “Development mechanisms and diagnostics of the lateral recess stenosis with the patients suffering from degenerative diseases of the lumbar spine”.
- Since 2008 has been working in the department of spine pathology in Sytenko Institute of Spine and Joint Pathology .
- Member of Ukrainian Association of Minimal Invasive Instrumental Spine Surgery since 2005.
- Member of ISMISS since 2009.
- The Participant of the international congresses SICOT/SIROT 2008, 2009.

# Diagnostics Of The Lateral Recess Stenosis

*Vladymyr Radchenko, M.D.; Artem Skidanov, PR.D.; Alexander Levshyn, PR.D.*

*Sytenko Institute of Spine and Joint Pathology, Kharkov, Ukraine*

1. Purpose of study. To improve the diagnostics of the lateral recess stenosis with the patients suffering from degenerative diseases of the lumbar spine.

2. Methods used. As the material for the clinical research we used the examination data of 110 patients suffering from the lumbar spine degenerative diseases. All the patients have been clinically examined, including neurological examination, Oswestry disability index study; roentgenometrical study of regular and functional spondylograms, spiral computer and magnetic resonance imaging tomography of the lower lumber spine. In addition, 92 tomograms of the lower lumbar spine of the patients under the age of 20 have been analyzed. Biomechanical study of the lumbar spine has been carried out with the help of mathematical modeling using finite element method. Classical methods of statistical data manipulation has been used for analysis.

3. Summary of findings. The number of symptoms that accompany lateral recess stenosis has been revealed in this thesis. They are: clinical, roentgenological, computer-tomographic, magnetic resonance tomographic symptoms. We have ascertained special features of the lumbar spine vertebral canal structure predisposing to the development of lateral recess stenosis and have proved their innate character. The character of the arc-shaped process joints asymmetry which brings on the development of lateral degenerative stenosis has been revealed. We studied the mechanisms of the disease's development with the help of mathematical modeling using the finite element method.

4. Relationship between findings and existing knowledge. It has been known for a long time that the trefoil form of lumbar spine is congenital. The possibility of the arthritic compression of nervous roots in the lateral section of the vertebral canal has been known as well. Our research has established the possible variants of the trefoil form of vertebral canal and specific peculiarities of facet joints constitution leading to the development of the lateral recess stenosis.

5. Overall significance of findings. The received data allowed not only to improve the diagnostics of the lateral recess lumbar stenosis but also gave rise to the further study of the development mechanisms of other degenerative spine diseases. Besides it is of great importance in the designing of facet joints implants.

The key words: lateral recess stenosis, vertebral canal, degenerative diseases, lumbar spine.

## Serdar Kabatas

Sex: Male
Nationality: Turkey
Present Address: Baskent University Istanbul Hospital, Department of Neurosurgery, Oymaci Sokak No:7 34662 Altunizade/Istanbul/Turkey
Phone: +90 216 554 15 00
FAX: + 90 216 651 97 46
E-mail: kabatasserdar@hotmail.com

**Professional Experience**

2008-current: Baskent University Istanbul Hospital, Department of Neurosurgery, Istanbul
2007-2008: Harvard Medical School, BWH/VA Hospital Spinal Cord Injury&Stem Cell Research Laboratory, Boston, USA
2005-2006: Ozel Bati Bahat Hospital, Department of Neurosurgery, Istanbul
2004-2005: Elazig Military Hospital, Department of Neurosurgery, Elazig
1998-2003: Istanbul University, Istanbul School of Medicine, Department of Neurosurgery, Istanbul
1997-1991:Trakya University, Faculty of Medicine, Edirne

**Education**

2008-current: Baskent University Istanbul Hospital, Department of Neurosurgery, Istanbul. Degree received Lecturer.
2007-2008: Harvard Medical School, BWH/VA Hospital Spinal Cord Injury&Stem Cell Research Laboratory, Boston, USA. Degree received Postdoctoral Fellow.
1998-2003: Istanbul University, Istanbul School of Medicine, Department of Neurosurgery, Istanbul. Degree received Specialist.
1997-1991: Trakya University, Faculty of Medicine, Edirne. Degree received MD.

**Award**

· Award of Turkish Neurosurgical Society Aysima Altınok, MD. (Specialization thesis): The Effect of One, Two and Three Level Cervical Laminectomy to the Cervical Spine Biomechanics (An Experimental Study on the Sheep-neck Model), May 2004, Antalya, Turkey

· Scholarship of Society of Nervous System Surgery in spine surgery, December 2005, Istanbul, Turkey

**Journal Articles (recent)**

· Kabatas S, Karasu A, Civelek E, Sabanci A, Hepgul KT, Teng YD. Microvascular decompression in the surgical management of trigeminal neuralgia: Long-term follow-up and review of the literature, Neurosurgical Review 32(1), 87-94, 2009

· Kabatas S, Yu D, He XD, Thatte HS, Benedict D, Hepgul KT, Black PM, Sabharwal S, Teng YD. Neural and anatomical abnormalities of the gastrointestinal system resulting from contusion spinal cord injury. Experimental Study. Neuroscience 154(4): 1627-38, 2008

· Kabatas S, Gümüş B, Yılmaz C, Caner H. CT-guided corticosteroid enjection as a therapeutic management for Piriformis Syndrome: Case report. Turkish Neurosurgery, 18(3): 307-10, 2008

# Radiofrequency Thermocoagulation of Ganglion Impar in the Management of Coccydynia: Preliminary Results

*Serdar Kabatas[1], Emre Demircay[2], Tufan Cansever[1], M. Gökhan Bilgili[2], Erdinç Civelek[1], Cem Yilmaz[1], Cengiz Tuncay[4], M. Nur Altinors[1]*

*[1]Department of Neurosurgery, Baskent University, Ankara, Turkey; [2]Department of Orthopedics and Traumatology, Baskent University, Ankara, Turkey*

**Introduction:** The efficacy of radiofrequency thermocoagulation (RFT) of ganglion impar in patients with chronic coccydynia was analyzed.

**Material and Methods:** We retrospectively evaluated the collected data of 10 patients with chronic coccydynia (pain > 6 months) who were treated by RFT of ganglion impar between October 2008 and May 2009. Visual Numeric Pain Scale (VNS) and descriptive system of health-related quality of life states (EQ5D) were used for patient assessment besides the physical and radiological examinations. All outcome measures were repeated at post procedure, 1 month and 6 months after the procedure.

**Results:** The mean age of the patients was 49.2 ± 14.4 (range 27-77). Among them, 8 were female (80 %) and 2 were men (20 %). Average follow-up was 9.1 ± 1.2 months. Statistically significant differences were observed between the pre-procedure and post-procedure VNSs ($p < 0.01$). Overall patient satisfaction was all successful in the short term. Midterm evaluation in post treatment (6 months) revealed that 90 % of the patients had successful outcome and 10 % were deemed failures.

**Conclusion:** Our data suggest that RFT destruction of ganglion impar in patients with chronic coccydynia has effective outcome and patients responding to RFT have significantly lower post-RFT pain scores in midterm follow up.

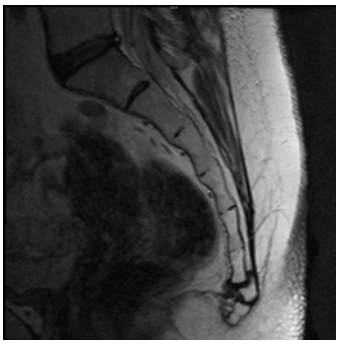

**Figure 1.** MRI view of posterior luxation of coccyx.


**Figure 2.** Needle placement through C1 – C2 intercoccygeal junction. Contrast distribution confined to the anterior of the coccyx and sacrum covering the location of ganglion impar.

# Postero-Lateral Approach For Anteriorly Located C2 Tumors: Report Of 2 Cases

*Cumhur Kilincer, Mustafa Kemal Hamamcioglu, Osman Simsek, Sebahattin Cobanoglu*

*Trakya Universitesi Tip Fakultesi Norosirurji Ad*

Anteriorly located cervical spinal cord neoplasms often require corpectomy and plating. This approach is difficult at the C2 level because the local anatomy generally requires a transoral approach. Thus, a posterior approach is preferred whenever feasible. It has been previously reported that anteriorly located spinal cord tumors could be removed using a posterior approach in some circumstances. In those cases, tumor-cord interface line should extend posteriorly to a horizontal line drawn along the posterior margin of the vertebral body. If that rule is satisfied, anteriorly located spinal cord tumors can be removed by the postero-lateral approach through a hemilaminectomy. The skin should be incised at the point where the tumor-cord line intersects. Using this technique, we operated two patients with anteriorly located C2 tumors (one cordoma and one meningioma). Intraoperative view and surgical exposition was satisfactory. In this study, we describe the cases and the surgical technique in detail.

## JOHN C. CHIU, M.D., FRCS (U.S.)

Medical Director, California Center for Minimally Invasive Spinal Surgery and California Spine Institute Medical Center,
1001 Newbury Road, Thousand Oaks, CA 91320, chiu@spinecenter.com

Dr. John C. Chiu is a pioneer in the field of endoscopic spinal surgery. He is the President of California Spine Institute Medical Center and the founding chairman of American Academy of Minimally Invasive Spinal Surgery and Medicine (AAMISMS). With extensive experience in minimally invasive spine surgery (MISS), he is actively involved in MISS clinical research, development and education. He received a D.Sc. degree in surgical research on Tissue Modulation Technology and was appointed a Professor of Minimally Invasive Spinal Surgery in Neurosurgery, and subsequently as the Provost of the American International University and President, ISMISS/SICOT (International Society of Minimally Invasive Spinal Surgery) in January 2007. Dr. Chiu is an adjunct Professor in Spine Surgery, Orthopaedic Surgery Dept. Faculty of Medicine, both at Ain Shams University, Cairo, Egypt, and at Hunan Medical University of TCM, and a Clinical Professor, The First Affiliated Hospital of Hunan University of TCM, Changsha, Hunan, China.

Dr. Chiu was involved in micro vascular neurosurgery and microspine surgery, before dedicating his practice to the advancement of minimally invasive spinal surgery and endoscopic spine surgery. He has been involved in the development of robotic surgery, telesurgery, OR of the Future, tissue modulation technology including laser thermodiskoplasty, and the use of radiofrequency and bipolar technology. He is an active advocate of redefining the algorhythm for the treatment of degenerative spinal disorders and spinal segmental motion preservation with MISS. He has served as a spinal consultant to eight companies related to MISS products and digital technology. He also served on a spinal advisory committee of one of the largest health care insurance companies, and as a special advisor/consultant to a State Department of Labor and Work Force Development. Recently he conducted the first interactive live Webcast on endoscopic MISS, with nearly 1,000 global participants and viewed by 3,000, and participated in a global tele-video web conference involving 3 continents (UCLA, USA, North America; Bordeaux, France, Europe; Korea, Asia).

He is the Editor in Chief for “The Internet Journal of Minimally Invasive Spinal Technology” and is a co-editor of the textbook “Practice of Minimally Invasive Spinal Technique” (2000 and 2005 editions) and on the editorial board of the journals “Surgical Technology International” and the “Journal of Minimally Invasive Spine Technique,” Dr. Chiu has authored numerous articles in peer review journal and 45 textbook chapters and other publications on MISS and related topics. He is a recipient of various honors and awards from professional societies, medical universities, and governmental entities, globally and in the US.

Dr. Chiu has lectured and performed spine surgeries throughout the world. He has held visiting professorships at universities worldwide and has served as course director for numerous spine surgery seminars and workshops both in the United States and abroad. He has written or presented over 800 papers (peer reviewed) at national and international scientific conferences, including North American Spine Society, American Academy of Neurological Surgeons, Congress of Neurological Surgeons, World Spine, World Congress of Neurosurgery, AAMISMS, ISMISS/

SICOT and other meetings. He also has demonstrated and performed numerous live endoscopic spine surgeries at major medical centers and university hospitals around the world. His patients have included international VIP's, leading medical professionals (neurosurgeons, spine surgeons, and others), top government officials, generals and even a head of state.

He has been invited as a lecturer, visiting professor, chairman of various conferences and keynote speaker on endoscopic MISS in numerous university medical centers, and in numerous conferences in countries including China, Hong Kong, India, Iran, Korea, Singapore, Taiwan, England, France, Germany, Greece, Italy, Luxembourg, Spain, Switzerland, Russia, Ukraine, Israel, Jordan, the Kingdom of Saudi Arabia, Marrakesh, Morocco, United Arab Emirates, Egypt, Brazil, Colombia, Mexico, Venezuela, Uruguay and others. Internationally, Dr. Chiu also has served as the honorary President of the Mexican Minimally Invasive Spine Surgery and Orthopedic and Trauma Society, Co-chairman of the 1st Chinese International Minimally Invasive Spine Surgery Congress, MISS China, 2007 and others.

Born in Fukien China, he received his medical degree from Baylor University College of Medicine and Neurosurgical training at the Mayo School of Medicine. Further training and fellowship were undertaken at the State University of New York, University of Zurich and the University of Lund in Sweden. Dr. Chiu is certified by the American Board of Neurological Surgery. Has served as an advisor/consultant for American Medical Foundation for Peer Review and Education for major teaching hospitals and medical staff to establish proper peer review and credentialing process.

His outside interests include playing the Chinese classical musical instrument, Guzheng (Zither) and practice of martial arts and its philosophy, as a grand master in kung fu, ninjitsu, and jujitsu. He participated in the International Martial Arts Tournament, St. Petersburg, Russia and is the recipient of the Martial Arts Lifetime Achievement Award, and the Martial Arts Pioneer Award as well as other awards, and an invited speaker for the Humanitarian Award in Martial Arts, U.S.A. International Black Belt Hall of Fame.

# Posterior Lateral Thoracic Endoscopic Microdiscectomy With Gps System

*John C. Chiu, M.D., Frcs, D.Sc*

*California Spine Institute*

**Purpose:**

To demonstrate the safety and efficacy of outpatient based endoscopic thoracic discectomy with laser thermodiskoplasty performed for symptomatic thoracic herniated nucleus pulposus.

**Materials and Methods:**

Since February 1996, 412 patients (516 discs) with symptomatic thoracic discs without myelopathy, who failed at least 12 weeks of conservative care, were treated. The technique of percutaneous microdecompressive endoscopic thoracic discectomy (with laser thermodiskoplasty) with GPS (Grid Positioning System) by posterolateral approach is described. The thoracic disc levels were T1 to T12. All patients demonstrated a contained soft thoracic disc herniation on MRI or CT scans. Intraoperative thoracic discogram and pain provocative tests were positive and confirmed the disc involved.

**Results:**

Preliminary postoperative follow-up demonstrates 90% of all patients had good to excellent and 6% fair symptomatic relief. The average time to return to work was ten days for the non-workers' compensation patients. Most of the patients received non-ablative lower laser energy application for thoracic disc shrinkage or tightening.

**Conclusion:**

Percutaneous microdecompressive endoscopic thoracic discectomy with GPS (Grid Positioning System) and application of non-ablative lower Holmium laser energy for disc shrinkage (laser thermodiskoplasty) appears to be easy, safe and efficacious. This less traumatic, easier outpatient treatment leads to excellent results, faster recovery, and significant economic savings

**References**

**1.**Chiu J, Javidan N., Thacker, J., Posteriorlateral Endoscopic Thoracic Microdecompressive Discectomy. The Internet Journal of Minimally Invasive Spinal Technology. 2008 Supplement I - to IJMIST Vol 1 No 2

**2.**Chiu J. Posterolateral Endoscopic Thoracic Discectomy. In: Kim D, Fessler R, Regan J, eds. Endoscopic Spine Surgery and Instrumentation. New York: Thieme Medical Publisher; 2004: Chapter 11 pp 125-136.

**3.**Jaikumar S, Kim D, Kam A. History of minimally invasive spine surgery. Neurosurgery 2002;51 Suppl2:1-14

**4.**Jaikumar S, Kim D, Kam A. Minimally invasive spine instrumentation. Neurosurgery 2002;51 Supp2:15-22

**5.**Perez-Cruet M, Fessler R, Perin N. Review: Complications of minimally invasive spinal surgery. Neurosurgery 2002;51 Suppl2:26-36

**6.**Chiu J, Clifford T, Sison R. Percutaneous microdecompressive endoscopic thoracic discectomy for herniated thoracic discs. Surg Technol Int 2002;10:266-269

**7.**Chiu J, Clifford T. Posterolateral Endoscopic Thoracic Discectomy: In: Savitz M, Chiu J, Rauschning W, Yeung A, eds. The Practice of Minimally Invasive Spinal Technique: 2005 Edition, AAMISS Press, New City, New York, 2005: 55:p 415-420

**8.**Fessler R, Khoo L. Minimally invasive cervical microendoscopic foraminotomy: An initial clinical experience. Neurosurgery 2002;51 Suppl2:37-45

**9.**Dickman C, Mican C. Thoracoscopic approaches for the treatment of anterior thoracic spinal pathology. Barrow Neur Inst Quart 1996;12:4-19

**10.**Nicholas T and Curtis AD. Current management of thoracic disc herniation, Cont Neurosurg 1996;18:1 7

**11.**Chiu J, Clifford T, Princenthal R. The new frontier of minimally invasive spine surgery through computer assisted technology. In: Lemke H.U, Vannier MN, Invamura RD, eds. Computer Assisted Radiology and Surgery. New York, NY: Spring-Verlag; 2002:233-237

**12.**Simpson J. Thoracic disc herniation. Spine 1993;18:872-1877

**13.**Schellhas KP, Pollei SR, and Dorwart RH. Thoracic discography: A safe and reliable technique. Spine, 1994;18:2103 2109

**14.**Chiu J, Clifford T. Percutaneous endoscopic thoracic discectomy. In: Savitz MH, Chiu JC, Yeung AD, eds. The Practice of Minimally Invasive Spinal Technique. Richmond, VA: AAMISMS Education, LLC;2000:2216

**15.**Chiu J, Clifford T. Posterolateral approach for percutaneous thoracic endoscopic discectomy. J of Minimally Invasive Spinal Technique. 2001:1:26-30

**16.**Chiu J, Clifford T. Microdecompressive percutaneous discectomy: Spinal discectomy with new laser thermodiskoplasty for non extruded herniated nucleus pulposus. Surg Technol Int 1999;8:343-351

**17.**Chiu J. Posterolateral Endoscopic Thoracic Discectomy.Lasers in Medical Science. London: Springer-Verlag Publisher; Oct 2004: 19:57

**18.**Chiu J, Posterolateral Endoscopic Thoracic Microdiscectomy,, World Spine III: The Third Interdisciplinary Congress on Spine Care, Rio de Janeiro, Brazil, 7/31-8/3/2005, Proceedings: pp. 2

**19.**Chiu J, Clifford T, et al, Percutaneous Microdecompressive Endoscopic Thoracic Discectomy for Herniated Thoracic Discs: In, Szabo Z,Lewis J, Savalgi R, Fantini G, eds. Surgical Technology International X, 2002 UMP, San Francisco, pp. 266-272

**20.**Chiu J, Clifford T. Percutaneous Endoscopic Thoracic Discectomy. In: Savitz M, Chiu J, Yeung A, eds. The Practice of Minimally Invasive Spinal Technique: 1st Edition 2000, AAMISM Education, Richmond, VA, 2000: 24; p 2216

**21.**Chiu J, Sheng Chen J. Thoracic herniated discs with 13 ribs: Case report. J Minim Invasive Spinal Tech. 2002;2(1):39-40

**22.**Savitz MH. Same day microsurgical arthroscopic lateral approach laser assisted (small) fluoroscopic discectomy. J Neurosurgery 1994;80:1039-1045

**23.** Chiu J, Posterior Lateral Endoscopic Thoracic Discectomy with Laser Thermodiskoplasty, Presented at the AAMISMS/MISU China 2007, Shanghai, Beijing, March 30-April 7, 2007, Proceedings; pp 11

**24.**Boriani S, Biagini R, Delure F. Two level thoracic disc herniations. Spine 1994; 21: 2461-2466

**25.**Coleman R, Hamlyn P, Butler P. Anterior spinal surgery for multiple thoracic disk herniations. Br J Neurosurg 1990;4:541-543

**26.**Dickman C, Mican C. Multilevel anterior thoracic discectomies and anterior interbody fusion using a microsurgical thoracoscopic approach. Case report. J Neurosurg 1996;84:104-109

**27.**Shikata J, Yamamuro T, Kashiwagi N. Multiple thoracic disc herniations: Case report. Neurosurgery 1988;22:1068-1070

**28.**Chiu J, Clifford T. Multiple herniated discs at single and multiple spinal segments treated with endoscopic microdecompressive surgery. J Min Inv Spinal Tech 2001; I:15-19

**29.**Clifford T, Chiu J, Rogers G. Neurophysiological monitoring of peripheral nerve function during endoscopic laser discectomy. J Min Inv Spinal Tech 2001;1:54-57

**30.**Chiu J, Clifford T, Savitz M A et al. Multicenter study of percutaneous endoscopic discectomy (lumbar, cervical and thoracic). J Min Inv Spinal Tech 2001;1:33-37

**31.**Chiu J, Savitz M. Multicenter Study of Percutaneous Endoscopic Discectomy: In: Savitz M, Chiu J, Rauschning W, Yeung A, eds. The Practice of Minimally Invasive Spinal Technique: 2005 Edition, AAMISS Press, New City, New York, 2005: 94:p622-626

# Minimally Invasive Endoscopic Spinal Surgery In The Management Of Pyogenic Spinal Infection.

*Akira Dezawa, Kouichi Sairyo, Tamio Kon*

*Department of Orthopaedic surgery Teikyo University Mizonokuchi hospital*

**Objectives:** To report clinical results of endoscopic surgery for pyogenic spinal osteomyelitis and spondylodiscitis and to evaluate the effectiveness of this procedure in treatment of pyogenic spinal infections.

**Summary of Background Data:** Spinal osteomyelitis and spondylodiscitis is frequently associated with elderly and compromised patients. Pyogenic spinal infections have been increasing due to the development of medical treatment for patients with comorbid medical problems. Thus, patients with spinal osteomyelitis who need surgery may benefit from minimal invasive techniques that avoid the complications of more extensive open approaches. We performed thoracoscopic and retroperitoneoscopic and percutaneous endoscopic posterolateral spinal surgery in patients with pyogenic vertebral osteomyelitis and spondylodiscitis, attempting to reduce the morbidity attributable to standard open surgery.

**Methods:** The technique and results of minimally invasive thoracoscopic spinal surgery for pyogenic vertebral osteomyelitis and spondylodiscitis in eleven patients, including radical debridement and anterior spinal reconstruction, are presented. 3patients in thoracoscopic approach 5 patients in retroperitoneoscopic approach, 3pateints in percutaneous endoscopic approach. Preoperative antibiotic treatment had failed in all the patients.

**Results:** All patients showed immediate pain reduction after surgery. Spinal fusion was obtained in 11 patients. Average of CRP was 7.00 mg/dl before surgery and 2.1 mg/dl at postoperative 3week. Radical debridement and anterior spinal reconstruction are feasible via endoscopic approach. Standard thoracotomy or thoracolumbar approaches associated with high morbidity can be avoided, even for fusion across multiple levels. Conversion to open technique was not necessary in this study. There was no recurrence of infection or loss of reduction during the follow-up period. Operative time and blood loss of endoscopic technique were comparable to open technique.

**Conclusions:** The cases clearly demonstrate the feasibility and efficacy of endoscopic spinal surgery in the management of pyogenic vertebral osteomyelitis and spondylodiscitis. Debridement, decompression of the spinal canal, interbody fusion, and anterior spinal fixation can be performed via endoscopic approach.

# The Transvertebral Herniotomy and its Expansive Indication.

*Sadaaki Nakai, Shuntaro Hanamura, , Naoyuki Shizu, Shunzo Tshjimura, Makoto Nishio*

*Department of Orthopedic Surgery, Fujita Health University School of Medicine, Toyoake City, Japan*

This study analyzed results of anterior transvertebral herniotomy for cervical disc hernia in order to assess the usefulness of this procedure and possibility of removal of upper thoracic disc hernia using same technique. The advantages of this method are the simplification of postoperative management and less risk of degeneration of the neighboring spinal segments, because the operated segments retain a variable degree of mobility.

**Materials**

Anterior transvertebral herniotomy was performed in 30 patients who had cervical disc herniation without spinal canal stenosis. The treated disks were C3/4 in 4 patients, C4/5 in 6 patients, C5/6 in 12 patients, C6/7 in 4 patients, C4/5 and C5/6 in 1 patient, and C5/6 and C6/7 in 3 patients.

**Methods**

Under general anesthesia, with the patient in the supine position, the side of the neck opposite to the herniated disc was incised for standard exposure of the anterior surface of the spinal column. If the herniated disc deviated cranially or caudally, the vertebral body on the side of deviation was exposed. Likewise, if there was lateral deviation of the herniated disc, the skin incision was made on the contra lateral side to the herniated mass, and the anterior surface of the vertebral body was exposed. Drilling was started with a high-speed drill at the center of the anterior surface of the adjacent cranial or caudal vertebral body. Drilling proceeded posteriorly or posterolaterally toward the herniated mass, and was stopped when the drill bit penetrated the posterior bone cortex. An operating microscope was introduced, and after checking the drilled-out posterior bone cortex, herniotomy was done through the drill hole, which was about 7 mm in diameter. The previously injected blue dye provided a good delineation of the herniated disc, especially if the mass had been extruded into the space between the superficial and deep layers of the posterior longitudinal ligament.

**Results**

In most patients, a good result was obtained, but simultaneous or subsequent anterior intervertebral fusion was necessary in 4 patients. In 1 patient, the two adjacent vertebrae had fused spontaneously.

**Discussion**

In patients with cervical disc hernia, not only radiculopathy but also myelopathy can be treated by this operation. However, in most patients with myelopathy the spinal canal is narrow relative to the spinal cord, so radiculopathy patients accounted for about a half of our series. The best indication for this treatment judging from our postoperative results is a large hernia associated with either myelopathy or radiculopathy in a patient without spinal canal stenosis. The most important points are that this procedure should be limited to localized soft disc hernias, and that bulging of the annulus fibrosus should be excluded. Recently Demura et al reported herniotomy between T2/3 using this technique. Usually sternal splitting approach is necessary for this level, therefore, this kind of approach may be useful if surgeons would like to treat patients minimally invasively.

**References**

Noguchi K et al: Anterior decompression for cervical spondylosis using microscope. Bessatsu Seikeigeka 13: 54-57, 1988 (Japanese)

Nakai S et al: Anterior transvertebral herniotomy for cervical disk herniation. J Spinal Disord 13: 16-21, 2000

# Identifying The Pain Generators In The Lumbar Spine: Bridging The Gap Between Interventional Pain Management And Traditional Spine Surgery With Endoscopic Techniques

*Anthony T. Yeung, M.D.,*

*Desert Institute for Spine Care, Phoenix, Arizona, USA*

**Introduction:** Interventional pain management physicians attempt to find pain generators with injection techniques. This usually only provides temporary pain relief, anticipating that the injection will mitigate the pain. The ability to place a needle in the vicinity of the pain source, however, and then visualize patho-anatomy with the endoscope has opened the door for access to the lumbar spine from T-10 to S-1. Endoscopic Spine Surgery is therefore possible with evolving modalities and techniques to address the patho-anatomy of pain. While traditional approaches provide standard proven and optimal access to spinal pathology, there are conditions better suited for the foraminal and posterior endoscopic approach. When a surgeon combines interventional techniques with endoscopic visualization, additional steps in the treatment algorhythm are available.

**Materials and Method:** A standardized method for endoscopic foraminal surgery (the YESS technique) is utilized: 1. A protocol facilitating needle and cannula placement for optimal instrument placement is calculated by lines drawn on the skin from the C-Arm image. This same trajectory is utilized for diagnostic and therapeutic injections as a precursor to endoscopic surgical intervention. 2. Injection of non-ionic radio-opaque contrast will result in a foraminal epiduralgram and produce foraminal epidural patterns that provide information on foraminal patho-anatomy such as HNP, and central and lateral spinal stenosis. 3. Evocative chromo-discography is performed to confirm discogenic pain and tissue removal is aided by the vital tissue staining. 5. Endoscopic foraminoplasty of the axilla of the exiting nerve is performed if lateral stenosis is visualized and the exiting nerve is tethered. 6. Diagnostic and surgical exploration of the epidural space is possible. 7. Probe the hidden zone of MacNab containing the exiting nerve, DRG, and axilla of the traversing and exiting nerve. 8. Using the biportal technique for inside-out removal of extruded and sequestered nucleus pulposus. 9. Dorsal endoscopic rhizotomy of the medial, intermediate and lateral branches of the dorsal ramus denervates the facet joint.

**Results:** The foraminal endoscopic and posterior technique will allow surgical access to the lumbar spine for treatment of a wide spectrum of painful degenerative conditions. There are, moreover, conditions where the endoscopic foraminal approach is advantageous over traditional surgical approaches. These conditions are 1. Discitis 2. Far lateral extraforaminal HNP, especially at L5-S1 3. Upper lumbar HNP. 4. Lateral foraminal stenosis 5. Discogenic pain from annular tears 6. Visualized endoscopic medial, intermediate, and lateral branch Rhizotomy. Case examples utilizing JPEG and MPEG imaging illustrate the painful conditions most suitable for foraminal endoscopic surgery.

**Conclusion:** New surgical skills will become desirable and necessary for the spine surgeon to incorporate endoscopic spine surgery in their practice. Incorporating interventional pain management helps bring additional clinical information that facilitates patient selection. New spinal procedures such as nucleus replacement, annular repair, annular reinforcement, and biologics are well suited for the foraminal minimally invasive approach. Endoscopic foraminal access to the lumbar spine will open the door for true minimally invasive access to the lumbar spine without affecting and destabilizing the dorsal muscle column.

# The New Technique for the Treatment of Osteoporotic Vertebral Fractures

*Darwono A. Bambang, MD*

*Department of Orthopaedic Surgery, Gading Pluit Hospital, Jakarta, Indonesia*

**Object**. Deramond (1984) introduced percutaneous non fusion technique to treat osteoporotic vertebral fractures. This technique Vertebroplasty is not intended to restore the vertebral body's height, but just freeze the fracture in situ. The injected cement with pressure will go to the weakest fracture's area and can lead to a leakage risk. Many techniques are then developed to restore the vertebral body's height by using tools that can create a hydrostatic or mechanical pressure inside the vertebra. Most technique then withdraw the tools, leaving a void inside the vertebra and filling it with cement like previous vertebroplasty so has the same risk of leakage. The new technique use a non stretchable PET container, injecting the cement inside the container and left it as an implant body expander. The container will prevent the leakage risk of the cement, but the interdigitation of cement mimics a controllable vertebroplasty and need a proper justification to end the procedure. The new SrHA cement is osteoinductive and osteoconductive materials with a less heat production, so it is suitable to be used in this technique. The purpose of this study is to review the theory, surgical techniques, results of 5 years using this new technique in restoring, stabilizing the vertebral body's height, and preventing the leakage risk of cement.

**Methods.** This new technique highlighting the Vessel-X™ system (A-Spine Holding Co) is a percutaneous non fusion technique to stabilize, restore VCFs, and prevent leakage risk of cement. Instead of previously creating a void inside the vertebral body, this system allows the delivery of a non stretchable PET container in deflated configuration then inflate by injecting the cement, and left as an implant body expander. The volume of the cement is controlled by a controllable cement delivery system injector with an extension tube. The pressure inside the container is created by the resistance of the PET container which is related to the amount of layer (1 or 2 layers), the pore size 100µ, and the size of container. The optimum pressure need to lift the end plate is the amount of pressure to counteract the resistance of the surrounding bone related to the bone density (old or young), fracture's age, fracture's line. When the pressure is over the surrounding bone resistance, the cement starts to penetrate the pores and interdigitate the surrounding bone thus stabilizing the container.

**Results.** A total of 250 cases of VCFs that have been treated using this new technique included 29 cases using SrHA cement is reported.

**Conclusions.** The Vesselplasty is a new technique to treat osteoporotic vertebral fractures using non stretchable PET container as implant body expander. This technique allows the stabilization and restoration of vertebral body's height, with the advantage in controlling the volume of the injected cement, the pressure inside the container, and preventing the leakage risk of cement.

# New Approach At Minimally Invasive Spinal Technique

*Radchenko V., Dedukh N., Malyshkina S.*

*Sytenko Institute of Spine and Joint Pathology, Kharkov,Ukraine*

**Introduction.**

New biomaterials and more advanced operative interventions are developed in spinal surgery. Application of new biomaterials demands their complex investigation.

**Purpose of investigation:**

To study the structure of the traumatized intervertebral disc after transplantation:

1. Of allogenic chondroblasts in combination with spinal restabilization using method of dynamic spine neutralization.
2. Chondroblasts in combination with bioactive ceramic.

**Matherials and Methods.**

After 9 days' growth the cells in culture of high-density were gotten cartilage differentiation and carry out transplantation its into traumatized intervertebral disc and performing dynamic stabilization.

For made stabilizing operation of the spine we used bioactive ceramic materials. Cultivated cells can be used for getting new property of calcium phosphate ceramics

**Results.** During morphometric investigation a disc height at the central and peripheral areas was measured. Using dynamic neutralization the intervertebral disc were shown increase of its height in middle on 16 % (in comparison with the injure discs).

The transplantation of chondroblasts into the disc injure was accompanied with an increase its height in all the investigated points – in the area of the trauma by 41 %, in the central area - by 19 %, and from the untraumatized part - by 16 %.

The transplantation of chondroblasts and using of dynamic neutralization also led to increase of height the intervertebral disc comparing to injure disc in all the investigated points: by 11; 26 and 22,2%. So, cultivated cells can be used for regeneration of disc.

Peculiarities of creating active "connecting" zone at the boundary "bone-ceramics" conditioning such properties of calcium phosphate ceramics are bioactivity and osteointegration were revealed. Osteoblasts which form bone tissue are located on the ceramic material. In the culture of cells the fact that hydroxyapatite induced differentiating mesenchimal cells in osteoblasts was experimentally confirmed.

**Conclusion.**

1. New technologies for repair intervertebral disc and vertebras were created
2. The transplantation of growing in vitro chondroblasts in traumatic defect of intervertebral disc carry out the cartilage regeneration
3. Cultivated cells closely contract with the ceramics and are located in their pores. High percentage of porosity provides free penetration of the cultural medium into ceramics promoting proliferation and growth of cells

# Minimally Invasive Procedures In DDD - Classification On Pain Generator: Intrinsic/ Extrinsic

*Pil Sun Choi*

*Orthopedic Institute Of University Of São Paulo, Hospital Abreu Sodré (Aacd),*

*Clinica Ortopedica Pacaembu (Private Clinic)*

**Objectives:**

To correlate the minimally invasive techniques with the type of the discogenic pain

**Summary of Background Data:**

With the advent of new minimally invasive spine procedures in the treatment of the degenerative lumbar disc disease, there was a need to create a didactic classification to facilitate the Brazilian's young spine surgeons to better understand the several different types of minimally invasive spine procedures and their applicability.

**Methods:**

We classified the minimally invasive spine procedures in: Intradiscal and Extradiscal for the treatment of the intrinsic and extrinsic lumbar discogenic pain.

**Conclusion:**

It's facilitate the young spine surgeon to have a better understanding on the applicability of different minimally invasive spine procedures for the treatment of the lumbar degenerative disc disease.

# Epidural Steroid Injections For Spinal Pain

*Elvan Erhan, MD, FIPP Professor, Department of Algology*

*Ege University, Faculty of Medicine, Izmir, Turkey*

In 1953 the French team Lievre et al. reported the first use of epidural steroids for the treatment of sciatica. Afterwards the report by Goebert et al. appeared to confirm the promising results epidural steroids offered in individuals suffering from radicular pain (1). Mechanical or chemical stimulation initiates a sequence of events responsible for the generation of back pain and radiculopathy. Mechanical irritation caused by compression, traction and/or chemical irritation result in intraneural inflammation characterized by ischemia, edema, fibrosis, and demyelination. As a result physiologic changes lead to an alteration of nerve function including muscle weakness, sensory deficit and/or hyperexcitability-pain (2). Steroids relieve pain by reducing inflammation, and by blocking transmission of nociceptive C fiber input (3). Lumbosacral epidural steroid injections are used for treatment for low-back pain with a radicular component secondary to lumbar disc pathology or spinal stenosis. The mechanism of therapeutic benefit is attributed to relieving the inflammation secondary to mechanical and/or chemical nerve root irritation. Corticosteroids have been shown to inhibit prostaglandin synthesis and impair the cell-mediated and humoral immune responses in addition to blocking nociceptive C fiber conduction (2).

Epidural steroid injections should be performed under fluoroscopic guidance because the injections may be outside the epidural space, or intravascular, resulting in the medication's missing the desired location. Access to the epidural space is available by caudal, interlaminar, and transforaminal approaches. Substantial differences with the technique and outcomes have been described among the 3 approaches. The response to epidural injections for various pathological conditions such as disc herniation and/or radiculitis, discogenic pain without disc herniation, spinal stenosis, and post surgery syndrome is variable. When using translaminar approach for epidural steroid injections, the epidural space is entered dorsally, which is distant from the source of pain and inflammation. Additionally, epidural postoperative scarring or extensive degenerative changes can also decrease the effectiveness of epidural steroid injections when using translaminar technique. The epidural space may also be approached transforaminally (4,5). This technique allows administration of medication closer to the site of pathology by delivering the injectate directly at the ventral aspect of the affected nerve root sleeve and posterior ramus.

Although epidural injection of corticosteroids is one of the most commonly used interventions in managing chronic spinal pain, there has been a lack of well-designed randomized, controlled studies to determine the effectiveness of epidural injections. Consequently, debate continues as to the value of epidural steroid injections in managing spinal pain. The effect of various types of epidural steroid injections (interlaminar, transforaminal, and caudal), in managing various types of chronic spinal pain have been evaluated in several systematic reviews (6,7). The primary outcome measure was pain relief (short-term improvement is defined as 6 weeks or less, and long-term relief is defined as 6 weeks or longer). There is limited evidence for interlaminar epidural steroid injections in the lumbar spine for long-term relief. The evidence for lumbar transforaminal epidural steroid injections is moderate for long-term improvement in managing nerve root pain. The

evidence for caudal epidural steroid injections is moderate for long-term relief in managing nerve root pain and chronic low back pain (6).

**References:**

1. Erjavec, 2001 M. Epidural steroids for low back pain. In: Loeser JD, ed. Bonica's Management of Pain, 3rd ed. Philadelphia, USA: Lippincott Williams and Wilkins; 2001; 1557-1564.
2. Raj, P.P. Epidural steroid injections. In: Raj P.P., ed. Practical Management of Pain, 3rd ed. St Louis, USA: Mosby Inc, 2000; 732-743.
3. Johansson, A., Hao, J., Sjolund, B. Local corticosteroid application blocks transmission in normal nociceptive C-fibers. Acta Anaesthesiol Scand 1990; 34: 335-338.
4. Lutz, G.E., Vad, V.B., Wisneski, R.J. Fluoroscopic transforaminal lumbar epidural steroids: an outcome study. Arch Phys Med Rehabil 1998; 79: 1362-1366.
5. Botwin, K.P., Gruber, R.D., Bouchlas, C.G., Torres-Ramos, F., Freeman, T.L., Warren, K.S. Complications of fluoroscopically guided transforaminal lumbar epidural injections. Arch Phys Med Rehabil 2000; 81: 1045-1050.
6. Abdi S, Datta S, Trescot AM, Schultz DM, Adlaka R, Atluri SL, Smith HS, Manchikanti L. Epidural steroids in the management of chronic spinal pain: a systematic review. Pain Physician. 2007;10(1):185-212.
7. Abdi S, Datta S, Lucas LF. Role of epidural steroids in the management of chronic spinal pain: a systematic review of effectiveness and complications. Pain Physician. 2005;8(1):127-43.

# A Novel Combination Of Facet Joint Injection And Sural Block For Low Back Pain And Sciatica

*Figen Yagmur Aslan*

*General Hospital*

A Novel combination of Lumbar facet joint injection and sural block in low back pain and sciatica (Disc herniation, foraminal stenosis and spondylolisthesis).

**Objectives:** Facet joint injection and sural block combination has not been described previously for lumbar radiculopathy in patients with a mild neurological deficit. In this study, we want to investigate the clinical effectiveness combination of joint injection and sural block in 208 patients with lumbar pathology (disc herniation, foraminal stenosis and spondylolisthesis). Spontaneus resorption of intervertebral disc herniation was determined.

**Patients and Methods:** Between May 2007 to and August 2009, 208 patients with radiculopathy was evaluated for foraminal stenosis, disc hernia and spondylolisthesis. Clinical criteria and pain map were used in selecting the levels to be blocked. Based on the clinical and imaging findings, surgery was justifiable in all cases. Pain commonly radiated in to the buttock and/or down to the thigh, extending to the foot usually. Single level block was used in 153 patients and double level block was used in 55 patients. f the patient passed more than two operation disc or fusion and had got any enstrumantation system that its create a problem for blocked were excluded this study. Fluoroscopically ( 4 or 8 magnified) guided system used for facet joint injection. Patient was informed before the facet joint injection and any level of pain its not resolved, operation will be thought for this level. All the patients were monitorized while during the procedure. We prefers to use 13 cc of % 1 lidocaine and 3 cc of 80 mg Depomedrol. 22 gauge, 1,5 inch spinal needels, two 10 cc syringe were used for lomber injection and 1cc depomedrol, 0.5 cc syringe was used for sural block at foot. All the patients take the analgesic and antienflamatuary drug and carbamazepin 200 mg /daily after the procedure. Under the floroscopy Y (joint nerve bifurcation demonstrated) shape was found and choosen for a target point in the middle of the pedicular area. Sural blocked performed in all the patients. f its necessary, one or two times sural block were added.After the injection combination 10 months and 1 year later, disc resorption percent was evaluated with MRI.

**Results:** They returned the daily activites 10 days, returned the their job 20-25 days later. The final outcome after facet joint injection and sural block was excellent in 186 (89%), and good in 14 ( 7% ), Fair 4 (4%). Conclusion: A novel combination of facet joint injection and sural block was found very effective to reduce the pain and disc volume.Pain map and injection theraphy should be very important aspect of the non operative treatment with lumbar pathology.njection combination helps to reduce the pain and resoption of the disc volume visibly.

# Foraminal Endoscopic Spine Surgery For Painful Degenerative Conditions Of The Lumbar Spine: Focus On Endoscopic Decompression Of Lateral Recess Stenosis

*Anthony T. Yeung, M.D.*

*Desert Institute For Spine Care Phoenix, Arizona, Usa*

**Introduction**

Minimally Invasive techniques in spine surgery have progressed rapidly in the past several years. Improvements in technique, endoscope design and instrumentation now make it possible for surgeons to safely access both the anterior and posterior column of the spine by through the foramen by using an endoscope for visualization.

The Posterolateral Approach vs traditional Approaches The foraminal approach is extremely versatile, allows access to the spine for discectomy, intradiscal and annular thermal modulation, foraminal decompression of central and lateral recess stenosis, facet cysts, and foraminal osteophytes. It can indirectly partially denervate the facet and aid anterior column stabilization. This approach is truly minimally invasive and tissue sparing.

**Thermal Modulation**

The use of thermal energy to shrink annular collagen and ablate pain nociceptors is a concept promoted by Saal and Saal, et al. The technique, called Intradiscal Electro-thermal Therapy (IDET) utilizes a thermal resistive coil to heat the disc that has a painful annular tear, with or without disc protrusion. The pain fibers in the disc and annulus are ablated at a temperature of 40-45 degrees C and the collagen of the annulus is contracted at 65 degrees C. The coil temperature must be gradually increased and held at 90 degrees C to get the temperature to 65 degrees at the annulus. While this technique may work in about 50% of patients without degenerative changes, it has limitations as a non-visualized technique that is dependent on very strict patient selection that cannot always be predicted by dependence on the MRI alone. Experience with discography and the proper interpretation of a painful discogram pattern is critical to patient selection. A pain management technique is being developed using a disposable annuloplasty Kit is currently under pilot study in the US and Europe..

**Selective Endoscopic**

Discectomy with Thermal Annuloplasty Most patients with degenerative conditions have a combination of disc protrusion, internal disc disruption, and facet mediated pain from the shifting of support from the anterior to the posterior spinal column. All disc herniations are amenable to foraminal endoscopic decompression in experienced hands.

**Foraminal Deompresson**

In the later stages, facet arthrosis and osteophytosis are present. Endoscopic access to the disc and to the posterior column through the foramen is readily accomplished through the postero-lateral portal. After removal of the degenerative portions of the disc, the annulus can be thermally treated, and then the foramen enlarged with mechanical instruments or laser ablation. Decompression is then accomplished by elevating the roof of the foramen by endoscopic resection of the superior articular process. If decompression is carried from the pedicle to the area of the exiting nerve root, the roof of the foramen is elevated. The floor of the foramen is lowered by resecting the annulus or removing the foraminal osteophytes. Lateral recess stenosis is especially amenable to endoscopic foraminal decompression. While decompressing the foramen, furcal

nerve branches or anomalous branches of the sympathetic trunk are sometimes seen during the decompression. These nerves have s role in the pain syndrome.

**Results**

Multiple retrospective studies have validated the YESS endoscopic technique in the treatment of disc herniation and degenerative conditions of the lumbar spine. Decompressing the lateral recess in spondylolisthesis and Failed Back Surgery Syndrome (FBSS) more recently expanded the indications of the YESS system. In a prospective study of 40 patients undergoing multi-level selective endoscopic disectomy and thermal annuloplasty reviewed independently by spine neurosurgeon Walter Bini, M.D., 32/40 (80%) responded favorably to a modified SF-36 and Oswestry questionnaire, indicating significant improvement of their back pain greater than 50% on a visual analog scale. All patients would do it again. There were no complications and no patient was worse. Another retrospective study by Yeung and Tsou, Selective endoscopic discectomy and thermal annuloplasty provided pain relief in 70% of patients with a wide spectrum of degenerative discs with positive discography. As foraminoplasty and dorsal branch rhizotomy were added to the procedure, additional iindications for nerve ablation increased, concomitant with the diligent evolution of the technique and decreasing learning curve. A prospective study using endoscopic medial branch and dorsal ramus rhizozomy provided 90% good/excellent results in patients with lumbar spondylosis and facet arthrosis.

**Conclusion**

The endoscopic foraminal technique is an excellent method for the treatment of painful degenerative conditions of the lumbar spine, ranging from discogenic pain to spinal stenosis.

# Intradiscal Therapies And Pain Management

*Halil Algan, M.D.*

*Acıbadem Hastanesi Agrı Tedavisi Bölümü*

Epidural abscesses can be seen after spinal interventions or spontaneously via hematogenous spread. Surgical debridement and drainage of the abscess is an important part of the treatment. Percutaneous endoscopic transforaminal approach is a new, safe and effective treatment modality.

A 62 year old male admitted to ER with complaints of sudden-onset severe headache, nausea and vomiting. Physical examination of the patient was consistent with neck stiffness; no other neurological deficit was identified. His past medical history showed lumbar disc surgery at the level of right L4-L5 10 years ago. Obtained cranial CT scan showed subarachnoid hemorrhage. The patient admitted to our neurosurgical clinic and cerebral digital subtraction angiography (DSA) obtained. There was no cranial vascular pathology except cerebral vasospasm seen in angiography. We performed whole spinal MR imaging which did not show any vascular pathology that can cause subarachnoid hemorrhage as well. We administered high-dose dexamethasone, antiepileptics and performed serial lumbar punctures. The patient was discharged after control cerebral DSA.

20 days later after the discharge the patient came back with severe low back pain radiating to his right leg. His neurological examination showed positive straight leg test on the right side. WBC count was 6900, CRP: 78.2, sedimentation 105mm/h. Visual analogue scale (VAS) was 9. MRI of the lumbar region showed epidural abscess at the level of L4-L5. We performed percutaneous endoscopic debridement and drainage of the abscess. Post-operative neurological examination revealed that straig leg test was negative, and VAS was 3. Post-operative early MRI showed that epidural abscess was drained successfully. Microbiological culture results came positive for methicilline sensitive staphylococcus aureus. 6 weeks of oral 2nd generation cephalosporin treatment is administered to the patient by infectious disease clinic.

Percutaneous endoscopic transforaminal approach is an appropriate treatment modality in surgical interventions. It is a safe and minimally invasive procedure.

## Nurettin Lüleci

Maltepe University Medical School Istanbul ,Turkey
GSM: + (90) 505 7470878
Work:+(90) 216 4440620/extension:1161

**Personal**
Place and Date of Birth: Izmit, Turkey, 1956
Sex: Male
Marital Status: Married

**Position**

2008-Present: Head of Anesthesiology and Reanimation Department — Istanbul, Turkey
Director of Algology Clinic
Maltepe University Medical School

2008-Professor of Anesthesiology and Reanimation Department — Istanbul, Turkey
Maltepe University Medical School

……-Director of Algology Clinic
Anesthesiology and Reanimation Department
Kartal Kofluyolu Training and Research Hospital — Istanbul, Turkey

……-Associate Professor- Celal Bayar University Medical School — Manisa, Turkey
Anesthesiology and Reanimation Department

1999-Asistant Professor- Celal Bayar University Medical School — Manisa, Turkey
Anesthesiology and Reanimation Department

**Education**

……-Ege University Medical School Algology Clinic — Izmir, Turkey

……-Karadeniz Technical University Medical School, — Trabzon,Turkey
Anesthesiology and Reanimation Department

……-Ataturk University — Erzurum,Turkey
Medical School

**Principal Areas Of Research And Teaching**

Pain management
- Treatment of the chronic pain
- Treatment of the spinal pain
- Treatment of the facet joint pain
- Treatment of the degenerative lumbar spine stenosis

Intradiscal therapies
- Percutaneous laser disc decompression
- Percutaneous ozone disc decompression

# Spongioplasty A New Percutaneous Method - Technique, Indications And Results

*Nurettin Luleci*

*Present: Head Of Anesthesiology And Reanimation Department Istanbul, Turkey*

*Director Of Algology Clinic Maltepe University Medical School*

"A new electrode is developed as a multifunctional electrode (PASHA-electrode) to diagnose the levels of the afferent fibres of nociceptive impulses that enter to the spinal cord and to apply the approprate treatment for those levels by using pulsed radiofrequency (PRF) at the dorsal root entry zone.

In opposition to radiofrequency thermocoagulation (RFTC), pluse radiofrequency works without overheating the dorsal roots and has fewer side effects. PRF treatment with PASHA-catheter modulates the spinal cord and it is a new way for the treatment of the pathways of the pain. This catheter possibly uses the electrical effects named as "neuroversion" as the immediate response and the transmitters for the delayed response. The main indication for this new device is neuropathic pain which originates from all levels of the spine, especially from the cervical region. PASHA-catheter can also be used for CRPS 1 (complex regional pain syndrome) and CRPS 2, failed back surgery, radicular pain which originates from both servical and lomber pathologies, multilevel spinal stenosis and restless leg syndrome effectively.

Using this new catheter with PRF at least 240 seconds seems to be effective for the chronic pain releated from the low back, thorax and especially the neck."

# The Epidural Cocktail For Management Of Lumbar Disc Bulge

*Mohamed Mohi Eldin*

*Cairo University*

In the dilemma of management of degenerative lumbar disc disease, I m offering a minimally invasive way of management. It is not, broadly speaking, a magic way, but , it can be, on personal basis.

# A Novel Technique Of Microsurgical Approach Through Laminofacet Articular Junction For Lumbar Disc Herniation (Hole Approach),Video Presentation

*Figen Yagmur Aslan*

*General Hospital*

A Novel technique of microsurgical approach through laminofacet articular junction for Lumbar Disc herniation (Hole approach),video presentation

**Objects:** Hole approach has not been described in lumbar disc herniation, previously. We aim to give details and results of a new operation technique, used in 548 patients with different localization and types of disc herniation.

**Methods:** Between March 2001 to January 2009, 548 patients with lumbar disc herniation underwent Hole approach. In this procedure, in order to expose facets of the inferior articular edge superior and inferior facets were removed minimally by high-speed drill. The facet capsule left intact which procedure was done by undercutting the facets to opened a hole (as large as a thumb nail) in the junction between the facets and the lamina. After the root was found, the disc was removed, yellow ligament opened minimally. Same side and controlateral side disc level were cleaned the same operation. Also the residue disc may be taken out from contralateral side by using this technique. (Patients were evaluated based on the presence of leg, back pain, length of time a return to daily activity) Patients data included; leg and back pain, return time to daily activity, Oswestry pain score, and final outcome. Patients were evaluated with post operative spiral CT and three dimensional reconstruction CT to show the amount of bone removing.

**Results:** Following the operation no one had leg or back pain. All patients were able to mobilize at to 4 hours, returned to daily activities at 5 to 7 days, and returned to their works at 15 to 21 days postoperatively. When compared with preoperative Oswestry pain score (46 3,3), postoperative score (3,1 0,9) was significantly decreased ($p<0,001$). The final The mean follow-up period was 40,2 months.

**Conclusion:** The goal of this approach were to protect to the facet articular joint, to used procedure in every type and size of disc herniation, to open the yellow ligament minimally, and this approach was used same side and controlateral disc removing.at the same operation. Hole approach is a very safe and effective by means of treatment for back pain and sciatica pain caused by disc herniation.

# A Novel Technigue Of Microsurgical Approach Trough Laminofacet Articular Junction For Foraminal Stenosis And Spondylolisthesis (Hole Aproaach),Video Presentation

*Figen Yagmur Aslan*

*General Hospital*

A Novel technigue of microsurgical approach trough laminofacet articular junction for foraminal stenosis and spondylolisthesis (hole Aproaach),video presentation

**Objectives:** Hole approach on the foraminal stenosis and spondylolisthesis has not been described previously. In this study, we aim to give details and results of a new operation technique, used in 163 patients with foraminal stenosis and spondylolisthesis. Patients and Methods: Between March 2001 and January 2009, 112 patients with foraminal stenosis and 51 patients with spondylolisthesis, who had conservative treatment before, were operated with hole approach. During operation a hole 0,5-1 cm was opened articular joint edge and conjunction between facet and lamina. At this approach minimaly inferomedial edge of the superior facet and superomedial edge of the inferior facet were drilled away by Anspach. Facet capsule leave intact. By guidance of the disc space, the portions and osteofit anteriorly, and medial face of the facet posteriorly were cleaned. Inferior and superior root conjunctions were exposed and interapophyseal space was released. Any instrumentation system and fusion were not used. Patients data included; leg pain, paresthesia, and weakness, return time to daily activity and Oswestry pain score and final outcome. Patients were evaluated with post operative spiral CT and three dimensional reconstruction CT to show the amount of bone removing.

**Results:** All patients were mobilized within 4-6 hr, discharged within 24-48 hr, sat down within 8-12 days, returned to daily activities and works within 15-25 days. Postoperative Oswestry pain score (3,41,7) was significantly decreased when compared with the preoperative pain scores (38,85,01) in the patients with foraminal stenosis ($p<0.001$). Preoperative and postoperative pain scores of the patients with spondylolisthesis were 41,75,5 and 3,7 1,2, respectively ($p<0.001$).

**Conclusion:** Hole approacch may be considered as a safe and effective a new procedure for the patients with foraminal stenosis and spondylolisthesis. This approach will be use multilevel segment and any instrumentation system were not used .

## Dr. Konstantyn Popsuishapka

Dr. K. Popsuishapka was born on 25th July 1974 in Kharkov (Ukraine). Internship was held in Kharkov municipal emergency hospital on the base of Kharkov National Medical University.

He is been working in the department of spine pathology in Sytenko Institute of Spine and Joint Pathology since 2000. and has got his medical degree in 2007.
He is a member of ISMISS from 2005, Ukrainian Association of Minimal invasive instrumental spine surgery from 2005.

The participant of the international congresses SICOT/SIROT 2005,2008; Eurospine 2006.

The Address: Sytenko Institute of Spine and Joint Pathology
Pushkinskaya str. 80, Kharkov, Ukraine 61024.
e-mail: ipps-noo@ukr.net

# Percutaneous automatic discectomy of cervical and lumbar spine

*Vladimir Radchenko, M.D.; Konstantyn Popsuyshapka PR.D; Alexander Levshyn, PR.D.*

*Sytenko Institute of Spine and Joint Pathology. Academy of Medical Science of Ukraine.*

At the present time different kinds of minimal invasive, neurosurgical technologies are widely used. There are percutaneous automatic discectomy, laser discectomy, radio-frequency discectomy etc., which can help to solve the problem of nucleus pulposus inner decompression in the cases of protrusion and hernias of cervical and lumbar discs.

In this we would like to share our experience of the treatment of discogenic pathology of cervical and lumbar spine by percutaneous automatic nucleotomy with the help of decompressor.

The material of investigation is the dates of 83 patients suffered from protrusions and hernias of cervical and lumbar discs. They have been treated since 2006-2009 by percutaneous nucleotomy with the help of decompressor. Nucleotomy has been performed on the cervical spine in 31 cases, $C_{V-VI}$ segment – 22 patients; $C_{VI}$-$C_{VII}$ segment – 9 patients. On the lumbar spine operation has been performed in 52 cases; $L_{III-IV}$ segment – 11 patients $L_{IV-V}$ segment – 29 patients, $L_{V-S1}$ – 6 patients; $L_{III-LIV-LV}$ segments – 3 patients; $L_{IV-LV-SI}$ segments – 3 patients. Age of patients was 17-66 years old.

# Coflex- Augmented Lumbar Microdecompression / Microlaminectomy, (Comparative Pilot Study)

*Mohamed Mohi Eldin*

*Cairo University*

**Objective:**

In this study, we selected patients older than 40 years of age with degenerative segmental stenosis & neurogenic claudication and analyzed whether the augmented lumbar microdecompression / microlaminectomy with the implantation of the coflex device is beneficial when compared with microdecompression / microlaminectomy surgery alone.

**Methods:**

Twenty five patients were treated with decompression augmented with the Coflex device, and 25 patients were treated with decompression alone during the same period. Clinical results were assessed using the pre- and postoperative visual analogue scale (VAS) and activities of daily living (ADL). Patients satisfaction was assessed using the validated outcome measurement, the Oswestry Disability Index Questionnaire (ODI). Radiologic results were assessed according to pre-and postoperative heights and segmental angles at the treated level.

**Results:**

The mean age of the patients in the Coflex device group was 46.9 years, and the in the decompression group was 50 years. The mean pre- and postoperative VAS scores were 8.8 and 3.4, respectively, in interspinous devices group and 7.2 and 2.2 in the decompression group. Both groups of patients showed significant improvement in their VAS and ADL scores in comparison with their preoperative scores. Radiologically, there were significant differences in disc heights and foraminal height between the two groups.

**Conclusions:**

The Coflex device was helpful in alleviating pain and improving ADL performance. It corrected segmental scoliosis and restricted extension. The addition of coflex device to the micro-decompression procedure, improves the clinical and radiological outcomes much, in properly-selected cases.

# Coflex Dynamic Interlaminar-Interspinous Distraction Stabilization Device For Lumbar Degenerative Diseases (Initial Experience)

*Mohamed Mohi Eldin*

*Cairo University*

**Aim of the study:**

The purpose of this study was to assess the safety and effectiveness of Coflex Dynamic Interlaminar-Interspinous Distraction Stabilization (DIDS) device (Paradigm Spine GmbH, Germany) in treating patients with degenerative diseases of the lumbar spine (DDLS), especially lumbar canal stenosis (LCS), to confirm its indications for implantation, and to evaluate the short-term clinical outcomes of patients.

**Material & Methods**

A total of 14 patients underwent placement of a coflex implant for various lumbar degenerative indications by one neurological spine surgeon. The mean follow-up was 7.5 months. The original indications for implantation were segmental form of stenosis, mild degree of degenerative retrololisthesis, or minimal 1st degree of degenerative spondylolisthesis. Preoperatively and postoperatively, patients were asked to grade their low-back and leg pain using the numeric verbal rating (NVR) scale for pain. Patients were asked about their satisfaction with the surgical procedure, using the validated Oswestry Disability Index Questionnaire (ODI). Follow-up radiographs were taken to determine any device-related issues.

**Results**

The most prevalent diagnoses for implantation were spinal stenosis. The mean severity of LBP decreased by 66% (from moderate to mild) at 3-month follow-up, and mostly disappear at the 1-year follow-up. Postoperatively 14 (100%) patients could walk >1000m. The results of pain relief throughout the study were best at late follow-up visits. Follow-up visits did show an increase of patients satisfaction. 13 patients (93%) stated that they would undergo this surgery again. Based on the follow-up radiographs, no patients had device-related issues.

**Conclusion**

The data provided have demonstrated that the coflex implant provides pain relief in indicated DDLS cases. Despite the limitations, the current study provides evidence that immediate pain relief and increase in function can be provided by the Coflex Device with a very low rate of morbidity.

# Cervical Percutaneous Nucleotomy

*Schubert, M, Helmbrecht, A.*

*Apex Spine Center*

**Headline:**

Compression fractures due to osteoporosis and osteoblastic tumors can be augmented with these techniques (vertebral augmentation). Vertebroplasty: Bone cement injection into compressed vertebral body. Kyphoplasty: Balloon inflation and bone cement injection into compressed vertebral body.

Indications are painful osteoporotic compression fractures and osteolytic metastatic tumors such as multiple myeloma. Contraindications are clotting disorders, painful situations not related to compression fractures, infection, insufficiant visualization, fractures that need stabilization, and bad general health condition.

**Method:**

Between August 2002 and February 2007 we have treated 75 patients with kyphoplasty technique. Indications were osteoporotic compression fracture (57), tumor related compression fracture (14) and traumatic compression fracture (4). Surgery was performed under general anesthesia (61 patients) or local anesthesia & conscious sedation (14 patients). Total number of vertebra treated is 103 (mean 1.4).

Surgical technique was percutaneous and bilateral transpedicular or unilateral extrapedicular needle insertion except one patient. Biplanar fluoroscopic control with one C-arm; verification of the needle first on lateral, then AP images, inflation of two balloons on each vertebral body with contrast media, high velocity acrylic was injected: 3 ml in thoracic, 5 ml in lumbar regions.

We also searched the literature to find out pros and cons of kyphoplasty and vertebroplasty.

**Result:**

More than 50% pain relief was achieved in all cases except one. There was no mortality and permanent morbidity. One patient had transient motor paralysis due to local anesthetic leakage to epidural space (spinal anesthesia). Paraspinal leakage of the cement is observed in 4 patients without any neurological or visceral compromise.

Kyphoplasty has advantages over vertebroplasty: Low rate of cement leakage, better technique to improve kyphotic deformity and lower rate of neurological complications. It is however, more expensive and may cause more radiation exposure.

More data are necessary to compare the two techniques in a prospective randomized fashion with standardized and validated methodology

# Percutaneous Laser Disk Decompression In Comparasion With Microdiscectomy

*Saftic R, Rotim K, Lakicevic G*

*Clinical Hospital "Sisters Of Charity", Zagreb, Croatia*

**Purpose:**

The purpose of this study was the evaluation of advantages in the procedure of percutaneous laser disk decompression in the treatment of lumbar disk herniation in comparison to open surgical methods on lumbar disk herniation like microdisectomy. Having access to the worlds neurosurgery literature we have found out that the percutaneous laser disk decompression is becoming an appropriate substitute for microdisectomy in surgical treatments of patients in cases of lumbar disk herniation.

**Material Or Subjects:**

From June 2008 till July 2009 in the Clinical hospital Sister of Mercy Zagreb 155 patients have been treated with percutaneous laser disk decompression and 125 patients have been treated with microdisectomy.

**Outcome Measures:**

we try to represent our experiences and results, which we have achieved by treating patients with lumbar disk herniation with PLDD procedures in contrast to patients treated with microdisectomy. Methods: The percutaneous laser disk decompression is done with the usage of a diode laser (LASE maR 1000), intensity of 1600 j, power 12 W and wave length 980 nm. Open surgical methods for lumbar disk herniation are performed with the surgical technique microdisectomy. The input and output criteria were the same for both groups of patients. The data achieved with the analyses of input and output parameters have been compared with the help of the MacNab criteria. There have not been found any statistically significant results in the comparison of data for age, sex and the stage of intervertebral disk herniation in both groups. This is a retrospective research and lasted 12 months.

**Results:**

Patients treated with the percutaneous laser disk decompression had in 89, 6 % ( n=139) very good or excellent results and were satisfied with the success of the treatment. In the group of patients treated with microdisectomy the number of patients, which had very good or excellent results, is minor and numbers 81, 2% (n=101). Postsurgical complications appeared in 1,2% ( n=2) in the group of patiens operated with percutaneous laser disk decompression. One patient had another percutaneous laser disk decompression and another patient had a METRx interlaminectomy. In the group of patients treated with microdisectomy, the number of patients, where complications appeared, is higher and numbers 6, 5% (n=8).

**Conclusion:**

The percutaneous laser disk herniation is a safer, simple and more effective method in treating patients with lumbar disk herniation in relation to open methods of treating lumbar disk herniation like microdisectomy.

# Correlation Between Preoperative Imaging Studies And Post-Operative Results In Lumbar Canal Stenosis – A Prospective Study

*Vijay G Goni, Sarvdeep S Dhatt, Nirmal Raj,Sudesh Pebam, Ashish Taneja And Naveen Tahashildar*

*Department Of Orthopaedic Surgery, Pgimer, Chandigarh 160012 India*

**Introduction:**

Although a lot of studies had been carried out in lumbar spinal stenosis (LCS) the absolute predictors for surgical management and predictable post-operative outcome were not evaluated using imaging studies. Hence it was considered worthwhile to look for this relationship using imaging studies and clinical analysis pre and post-operatively

**Methods**:

Fifty patients in the age group of 25 to 70 years who underwent surgical treatment for lumbar spinal Stenosis at our hospital were included in the study. Preoperatively the cases were evaluated with the Oswestry disability index. All 50 patients underwent preoperative L-S spine roentgenograms and Magnetic Resonance Imaging. The various stenotic levels were identified. The stenotic dural sac on MRI was measured using the UNIX and AutoCAD software and compared to the deficit. Post-operative neurological status assessment was also carried out using the Oswestry disability index

**Results:**

Out of 50 patients, 36 were males and 14 were females and 43 % cases were smokers. The mean preoperative and post-operative Oswestry disability indexes were 71 +/- 4 % and 22 +/- 6 % respectively. All cases had relative to severe stenosis on MRI with the mean dural cross sectional area 75 mm2 at L 4-5 and 76 $mm^2$ at L5-S1 levels respectively. The various stenotic levels were identified as those with facet hypertrophy, ligamentum flavum hypertrophy and disc prolapse. Laminectomy and disectomy was the commonest procedure performed in 54 % of the cases. The satisfaction level based on the Oswestry disability questionnaire was calculated.

**Conclusion:**

Clinico-radiological assessment of lumbar spinal stenosis and evaluation of surgical treatment was done and it showed that there is a correlation between the severity of stenosis on MRI and the neurological deficit. Surgery was beneficial and showed good to excellent results.

# Integrated Outcome Assessment After Anterior Cervical Discectomy, Fusion (ACDF) With Autograft And Plating In Cervical Spodylomyelopathy

*Dr.Vijay G Goni, Dr. Vishal Kumar, Dr. Naveentahasildar*

*Post Graduate Institute Of Medical Education And Research (Pgimer), Chandigarh, India 160012*

**Introduction:**

Cervical spondylotic myelopathy (CSM) is the most common cause of cord dysfunction in patients over 55 years of age. Involvement of the C5-6 is frequent, followed by C6-7 and C4-5. The diagnosis of cervical spondylotic myelopathy is primarily based on a thorough clinical and radiological examination. Anterior cervical discectomy and fusion (ACDF) is the standard of care for cervical spondylomyelopathy. Autogenous cancellous bone, taken from the iliac crest was used in cervical fusion. Plating provides rigid fixation, resists setting and development of segmental kyphosis, promotes higher fusion rates, allows for less cumbersome external immobilization and reduces the incidence of graft extrusion. The anterior approach through modified Smith- Robinson technique is less disruptive to the neck musculature and arthrodesis can be adequately performed from C2-T2.

**Methods:**

Twenty patients with mean age of 58.5 years with clinical and radiological evidence of CSM underwent ACDF with autograft and plating were prospectively studied for a mean duration of 2.8 years. Multilevel (>3) cervical spondylosis with neutral or lordotic, kyphotic sagital alignment, degenerative segmental instability without anterior compressive pathology or kyphosis, anterior pseudoarthrosis without associated kyphosis, congenital cervical stenosis, post-traumatic were excluded from the study. Clinical outcome was assessed using signs and symptoms based on selected items of Odom's criteria, Japanese Orthopaedic Association (JOA) Score and Nurick's grading. All patients received pre-operative and post-operative conventional (anterior-posterior, lateral) and functional (flexion/extension) radiographs and MRI.

**Results:**

At final follow up, symptoms resolution remained greater than 92% and fusion occurred in 94% of the disc spaces operated on. No graft extrusion / migration or implant complications are yet reported. Post-operatively, MRI signs of myelopathy defined as high signal foci of spinal cord in T2 – weighted images with or without a focal dimensional change in T1 – weighted images disappeared in 90% of the patients. All pre-operative and post-operative differences are significant at the $p < 0.001$ levels.

**Conclusion:**

There is integrated improvement of radiologic signs, clinical signs and symptoms and quality of life in patients with cervical spondylotic myelopathy after anterior cervical discectomy and fusion with autograft and plating.